



**HAL**  
open science

## Organization for Caries Research-European Federation of Conservative Dentistry Consensus Report on Clinical Recommendations for Caries Diagnosis Paper II: Caries Lesion Activity and Progression Assessment

Klaus W Neuhaus, Jan Kühnisch, Avijit Banerjee, Stefania Martignon, David Ricketts, Falk Schwendicke, Monique H van der Veen, Sophie Doméjean, Margherita Fontana, Adrian Lussi, et al.

### ► To cite this version:

Klaus W Neuhaus, Jan Kühnisch, Avijit Banerjee, Stefania Martignon, David Ricketts, et al.. Organization for Caries Research-European Federation of Conservative Dentistry Consensus Report on Clinical Recommendations for Caries Diagnosis Paper II: Caries Lesion Activity and Progression Assessment. Caries Research, 2024, 58 (5), pp.511-520. 10.1159/000538619 . hal-04742195

**HAL Id: hal-04742195**

**<https://uca.hal.science/hal-04742195v1>**

Submitted on 17 Oct 2024

**HAL** is a multi-disciplinary open access archive for the deposit and dissemination of scientific research documents, whether they are published or not. The documents may come from teaching and research institutions in France or abroad, or from public or private research centers.

L'archive ouverte pluridisciplinaire **HAL**, est destinée au dépôt et à la diffusion de documents scientifiques de niveau recherche, publiés ou non, émanant des établissements d'enseignement et de recherche français ou étrangers, des laboratoires publics ou privés.



Distributed under a Creative Commons Attribution - NonCommercial 4.0 International License

# Organization for Caries Research-European Federation of Conservative Dentistry Consensus Report on Clinical Recommendations for Caries Diagnosis Paper II: Caries Lesion Activity and Progression Assessment

Klaus W. Neuhaus<sup>a,b,c</sup> Jan Kühnisch<sup>d</sup> Avijit Banerjee<sup>e</sup> Stefania Martignon<sup>f</sup>  
David Ricketts<sup>g</sup> Falk Schwendicke<sup>d,h</sup> Monique H. van der Veen<sup>i,j</sup>  
Sophie Doméjean<sup>k,l</sup> Margherita Fontana<sup>m</sup> Adrian Lussi<sup>b,n</sup>  
Anahita Jablonski-Momeni<sup>o</sup> Fausto Medeiros Mendes<sup>p</sup> Gail Douglas<sup>q</sup>  
Gottfried Schmalz<sup>r,s</sup> Guglielmo Campus<sup>b,t</sup> Johan Aps<sup>u</sup> Keith Horner<sup>v</sup>  
Niek Opdam<sup>w</sup> Marie-Charlotte Huysmans<sup>w</sup> Christian H. Splieth<sup>x</sup>

<sup>a</sup>Department of Pediatric Oral Health, University Center for Dental Medicine Basel (UZB), University of Basel, Basel, Switzerland; <sup>b</sup>Department of Restorative, Preventive and Pediatric Dentistry, School of Dental Medicine, University of Bern, Bern, Switzerland; <sup>c</sup>Department of Dermatology, Inselspital, Bern University Hospital, University of Bern, Bern, Switzerland; <sup>d</sup>Department of Conservative Dentistry and Periodontology, University Hospital, Ludwig-Maximilians Universität München, Munich, Germany; <sup>e</sup>Conservative and MI Dentistry, Faculty of Dentistry, Oral and Craniofacial Sciences, King's College London, London, UK; <sup>f</sup>UNICA – Caries Research Unit, Research Department, Universidad El Bosque, Bogotá, Colombia; <sup>g</sup>Unit of Restorative Dentistry, University of Dundee, Dundee, UK; <sup>h</sup>Department of Oral Diagnostics, Digital Health and Health Services Research, Charité – Universitätsmedizin Berlin, Berlin, Germany; <sup>i</sup>Departments of Preventive Dentistry and Paediatric Dentistry, Academic Centre for Dentistry Amsterdam, University of Amsterdam and VU University, Amsterdam, The Netherlands; <sup>j</sup>Oral Hygiene School, Inholland University of Applied Sciences, Amsterdam, The Netherlands; <sup>k</sup>Département d'Odontologie Conservatrice, UFR d'Odontologie, Centre de Recherche en Odontologie Clinique, Université Clermont Auvergne, Clermont-Ferrand, France; <sup>l</sup>Service d'Odontologie, CHU Estaing Clermont-Ferrand, Clermont-Ferrand, France; <sup>m</sup>Department of Cariology, Restorative Sciences and Endodontics, University of Michigan School of Dentistry, Ann Arbor, MI, USA; <sup>n</sup>University Hospital for Conservative Dentistry and Periodontology, Medical University of Innsbruck, Innsbruck, Austria; <sup>o</sup>Department of Orthodontics, Dental School, Philipps University Marburg, Marburg, Germany; <sup>p</sup>Department of Pediatric Dentistry, Faculty of Dentistry, University of São Paulo, São Paulo, Brazil; <sup>q</sup>Department of Dental Public Health, University of Leeds School of Dentistry, Leeds, UK; <sup>r</sup>Department of Conservative Dentistry and Periodontology, University Hospital Regensburg, Regensburg, Germany; <sup>s</sup>Department of Periodontology, University of Bern, Bern, Switzerland; <sup>t</sup>Department of Surgery, Microsurgery and Medicine Sciences, School of Dentistry, University of Sassari, Sassari, Italy; <sup>u</sup>OpiniDent BV, Kortrijk, Belgium; <sup>v</sup>Division of Dentistry, School of Medical Sciences, Faculty of Biology, Medicine and Health, Manchester Academic Health Science Centre, University of Manchester, Manchester, UK; <sup>w</sup>Department of Dentistry, Radboud University Medical Center, Nijmegen, The Netherlands; <sup>x</sup>Department of Preventive and Pediatric Dentistry, University of Greifswald, Greifswald, Germany

---

## Keywords

Diagnosis · Caries · Activity · Progression · Consensus

---

## Abstract

**Introduction:** This consensus paper provides recommendations for oral health professionals on why and how to assess caries activity and progression with special respect to the site of a lesion. **Methods:** An expert panel was nominated by the executive councils of the European Organization for Caries Research (ORCA) and the European Federation of Conservative Dentistry (EFCD). The steering committee built three working groups that were asked to provide recommendations on (1) caries detection and diagnostic methods, (2) caries activity and progression assessment, and (3) obtain individualized caries diagnoses. The experts of work group 2 phrased and agreed on provisional general and specific recommendations on caries lesion activity and progression, based on a review of the current literature. These recommendations were then discussed and refined in a consensus workshop followed by an anonymous Delphi survey to determine the agreement on each recommendation. **Results:** The expert panel agreed on general ( $n = 7$ ) and specific recommendations ( $n = 6$ ). The specific recommendations cover coronal caries on pits and fissures, smooth surfaces, proximal surfaces, as well as root caries and secondary caries/ caries adjacent to restorations and sealants. 3/13 recommendations yielded perfect agreement. **Conclusion:** The most suitable method for lesion activity assessment is the visual-tactile method. No single clinical characteristic is indicative of lesion activity; instead, lesion activity assessment is based on assessing and weighing several clinical signs. The recall intervals for visual and radiographic examination need to be adjusted to the presence of active caries lesions and recent caries progression rates. Modifications should be based on individual patient characteristics.

© 2024 The Author(s).

Published by S. Karger AG, Basel

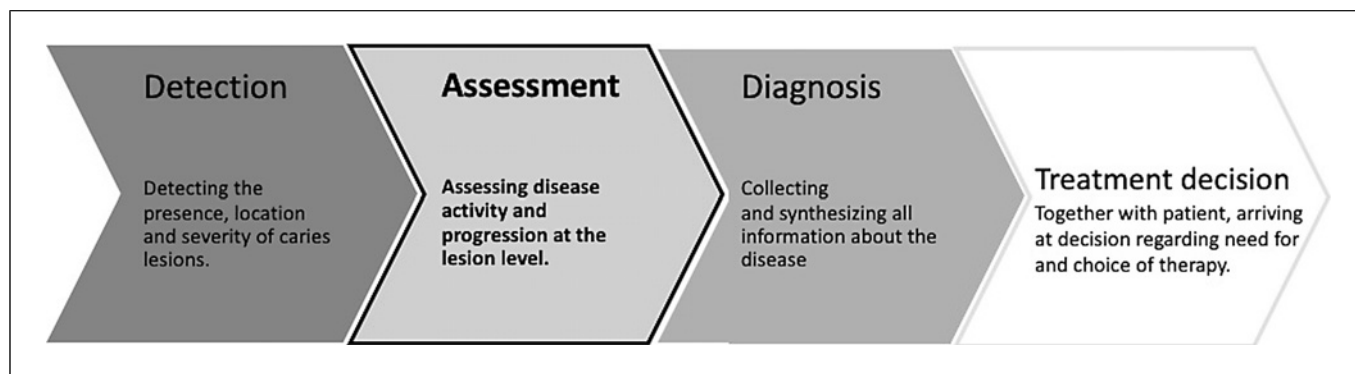
## Introduction

The contemporary holistic approach to dental caries management includes preventive and therapeutic aspects as part of a patient-focused, oral healthcare team provided minimum intervention oral care delivery strategy in order to control caries as a chronic disease [1, 2]. The European Organization for Caries Research (ORCA) and the European Federation of Conservative Dentistry (EFCD) have published a series on evidence-

based consensus statements on how to control caries in children, adults, and seniors [3–8]. Caries management requires a valid diagnosis of different parameters in the caries process such as staging and lesion activity assessment (LAA) and lesion progression assessment (LPA). Therefore, ORCA and EFCD initiated guidance on how to detect, assess, and diagnose caries. This paper presents the results of the working group dealing with LAA and LPA. After summarizing, the current literature, expert consensus statements are presented to offer oral healthcare providers a guidance on assessment of caries lesion activity as a basis for development of a best practice evidence-based caries management plan.

In order to outline the scope of the present paper, it is mandatory to define the concept of caries LAA. While caries is a dynamic process that can, over time, progress, arrest, or regress, lesion activity is independent of the lesion depth and rather depends on the ability to remove surface biofilm [9]. After a thorough debate at an ORCA terminology workshop, there was unanimous agreement that caries lesion activity is a concept that reflects the mineral balance, in terms of net mineral loss, net mineral gain, or stasis over time [2]. “Caries active” implies caries initiation/progression and “caries inactive” implies caries arrest or reversal [10]. Caries is a multifactorial disease whose underlying dysbiotic cariogenic undisturbed biofilm leads to net mineral loss of dental hard substance over time. Thus, “true” caries activity assessment at the disease level would be the assessment of the caries lesion biofilm metabolism and its cariogenicity since caries lesion activity is dictated by the metabolic acid-producing activity within the biofilm on the surface of the lesion. While attempts have been made to assess this metabolic activity on tooth surfaces with impregnated impression materials [9, 11], or with site-specific bacteria tests [12], no such methods have gained acceptance in general oral health practice.

In contrast, using clinical observations and an understanding of the underlying biological etiology of caries, the LAA that this paper deals with is the *real-time* assessment of lesion surface characteristics and/or a subset of other clinical signs. Clinical signs observed in non-cavitated and cavitated (dentine) caries lesions, such as change of lesion surface texture, translucency, color, and other factors such as the presence of dense or sticky plaque covering the lesion surface, or the lesion’s localization in a plaque stagnation area as well as local gingivitis help inform on the likelihood of a lesion progressing or not [9, 13–21]. Different LAA systems include



**Fig. 1.** Order of steps in the caries lesion decision-making process.

different combinations of these signs, with varying emphasis placed on each factor.

It is a well-established clinical observation that caries risk/susceptibility is closely linked with caries activity: lesions in high risk patients are more likely to be active and progress than lesions in low-risk patients. However, local conditions are relevant, and it does not follow that patients with an increased caries risk have active lesions per se. Thus, because LAA also takes features into account that are beyond the mere lesion surface, it is important to differentiate LAA from caries risk/susceptibility assessment. Again, the ORCA/IADR terminology points out that caries risk is a proxy for the true outcome (new lesions or progression) which can only be validated over time [2]. Thus, patient caries risk/susceptibility as a probability and prognosis assessment into the future (originally for healthy tooth surfaces to develop the disease; or for inactive lesions to become active again) can be separated from the concept of caries activity and progression where signs and symptoms of the chronic caries process are already present. These can be projected into the future or modified in the process of caries management in order to control future lesion development [2]. Consequently, LAA plays a crucial part in lesion monitoring and evaluation of nonoperative treatment outcomes.

Active caries lesions require nonoperative and/or operative care. Thus, the LAA is essential in the decision-making process of caries management (Fig. 1). LAA deals with assessing the local signs that are linked to lesion dynamics. Therefore, the best validation of lesion activity is the repeated lesion assessment over time. Such longitudinal reassessment is one of the core requirements in patients' recall appointments, and it can also help validate the effectiveness of nonoperative preventive regimes that are performed for lesions originally classified as "active."

The aim of this paper was, therefore, after thorough screening of the available literature, to summarize and

provide consensus-based, practical clinical recommendations to assess lesion activity and lesion progression, to be useful for primary care practice.

### Materials and Methods

After the agreement on the need for this consensus process, participants were selected and invited by the boards of the EFCD and the ORCA, aiming for a well-balanced representation of experts in the fields of cariology, restorative dentistry, paediatric dentistry, and gerodontology. The experts were split up into three working groups with the focus on detection [22], activity assessment, and diagnosis [23] (Fig. 1) lead by a joint steering group (M.-C.H., J.K., C.H.S., K.W.N.).

The starting point for the consensus on LAA and LPA (Fig. 1, step 2) was a literature review of studies validating LAA and methods related to LPA. CS entered the search terms "caries" and "activity" on 7th of May 2021 into PubMed/Medline and received 1,617 hits. Due to several recent systematic reviews on this topic, the additional restriction to systematic reviews of the last 5 years led to 32 citations which were selected according to their relevance with the topic. The equivalent search for "caries" and "progression," resulted in 24 hits. The original literature in the references of these 32 and 24 systematic reviews, respectively, were scanned, and all group members were invited to add further relevant literature.

After considering the literature, the working group met twice online, discussed, and agreed on a site-specific structure for recommendations regarding LAA, for example, for pit and fissure surfaces, proximal/smooth surfaces, root caries, and caries adjacent to restorations and sealants (CARS) lesions. It was also decided that general recommendations applying to all tooth surfaces would be helpful for dental practitioners. After drafting the recommendations and the relevant literature in the working and steering groups, the manuscript was sent to the members of the two other working groups for comments. These changes were discussed in an online meeting of all three groups on August 31st, 2022 in order to achieve a suitable consensus for the recommendations from the whole board. Members who were not able to attend the online meetings agreed via email with the outcome, and they were equally involved in the subsequent voting process as well

as in the manuscript writing. This online process, including the workshops, did not have any relevant financial costs, no honoraria were paid, and all participants had to declare potential conflicts of interest which are stated at the end of this paper.

The online meeting followed the procedures of the first ORCA/EFCD consensus process [3–8]. Each statement was discussed extensively and modified until consensus was reached. The level of agreement of each recommendation was evaluated by the group and categorized as “high,” “moderate” or “low,” based on the scientific evidence supporting each statement. Recommendations supported by unequivocal evidence (e.g., multiple randomized controlled clinical trials) were evaluated as “high.” Recommendations based on moderate evidence (e.g., high-quality clinical studies, such as randomized controlled trials with similar results) were evaluated as “moderate.” Finally, recommendations based on expert opinion only and that are based on weak evidence (e.g., no clinical studies or only low-quality studies or studies with contradicting results) were ranked as “low.”

Based on the discussions at the meeting, the present manuscript was drafted by the steering group and sent to the overall group, who commented on it extensively, in two rounds. Afterward, similar to earlier ORCA/EFCD consensus papers (1–8), a confidential e-Delphi survey (Castor EDC, Amsterdam, The Netherlands) was finally undertaken, and every single recommendation was ranked by each participant independently. The text itself (excluding the recommendations) was not submitted to any further consensus process.

The voting on each statement was graded from 1 (completely disagree) to 10 (completely agree). At least 70% of the vote  $\geq 8$  was considered as acceptance of the statement by the group, and the results were reported as agreement (10–8), (neutral 7–4) or disagreement (3–1). In addition, the median of all votes was calculated. An additional field for free-text comments was also available to allow the reasoning for a certain decision or proposals for future modifications. Before the submission of the manuscript, all authors consented to the content.

## Recommendations

During the discussion, the working group felt that there are general recommendations to be made, which address all tooth surfaces, and specific recommendations, which are applicable solely for specific tooth surfaces. Moreover, some recommendations concern the methodology of carrying out LAA in patients. These methodologic recommendations are not graded with a level of evidence, only with a level of agreement among experts.

## General Recommendations

The dynamic nature of dental caries implies phases of progression or stagnation. Active caries lesions are at higher risk for lesion progression [15], and thus, by definition, recently developed caries lesions or lesions that have progressed have been active caries lesions.

**General recommendation 1:** Consider progressed and recently developed caries lesions as active caries lesions.

Level of evidence: moderate.

Level of agreement: 100% (agree,  $N = 20$ ).

The primary method for lesion detection is the visual-tactile assessment [22]. The same is true for LAA. Although attempts have been made to enhance the LAA with auxiliary methods such as laser fluorescence, quantitative light-induced fluorescence, optical reflectometry, perpendicular reflection intensity, bioluminescence, or thermal imaging, these methods either lack robust clinical evidence or have not gained clinical practicability.

**General recommendation 2:** The visual-tactile examination should be the method of choice for caries lesion activity assessment. Other auxiliary methods are not recommended for this purpose.

Level of evidence: moderate.

Level of agreement: 80% (agree,  $N = 16$ )/15% (neutral,  $N = 3$ )/5% (disagree,  $N = 1$ ).

Surface texture/roughness plays an important role in LAA, as does the assessment of surface sheen, hardness (in root and coronal dentine caries lesions), bleeding on probing in adjacent gingivae, or the presence of a pre-existing mature and dense overlying biofilm [15, 18, 24]. Depending on the clinical situation (e.g., after professional mechanical tooth cleaning), one or more features may be less visible or detectable.

**General recommendation 3:** Lesion activity assessment should be based on evaluating and weighing up several clinical characteristics, as no single feature is indicative for caries lesion activity.

Level of evidence: moderate.

Level of agreement: 100% (agree,  $N = 20$ ).

Cavitated caries lesions that are not readily cleansed mechanically, as might be the case in cavitated enamel or root caries, or in CARS, allow undisturbed biofilm formation and are usually associated with active lesions [15, 18]. For this reason, a core principle of caries management is to reestablish cleansability [3–8].

**General recommendation 4:** Non-cleansable cavitated caries lesions should be considered as active unless there are clear signs of inactivity.

Level of evidence: low.

Level of agreement: 95% (agree,  $N = 19$ )/5% (neutral,  $N = 1$ ).

Although the result of LAA is dichotomous, i.e., either “active” or “inactive,” the presence of so-called “mixed lesions” has also been described [15]. Mixed lesions typically are not necessarily deep lesions with a large circumference but may occur at any tooth aspect and show features of both caries activity and inactivity. Furthermore, depending on when LAA was carried out in the clinical workflow, there might be missing clinical information that is necessary for LAA, for example, if professional mechanical tooth cleaning has been performed in advance and all surfaces are subsequently plaque-free and polished, or if the teeth have recently been air-polished, causing gingival bleeding. Consequently, there might be detectable lesions, but the clinician is uncertain about their activity.

**General recommendation 5:** Non-cavitated caries lesions with uncertain activity status should be regarded as active caries lesions until reevaluation.

Level of evidence: –.

Level of agreement: 85% (agree,  $N = 17$ )/10% (neutral,  $N = 2$ )/5% (disagree,  $N = 1$ ).

The timepoint to carry out LAA has been subject of considerable academic debate. While a dense and sticky plaque biofilm covering an enamel lesion is indicative for an “active” lesion due to chronic neglect of mechanical cleaning [15], its very presence hampers the important clinical step of lesion detection. Therefore, most LAA protocols replace the presence of a biofilm with the criterium, “plaque stagnation area” (i.e., pits and fissures, or close to the gingival margin, and/or a triangle beneath the proximal contact area adjacent to a tooth or a gap). This follows the logic that a lesion has first to be detected before its activity can be assessed [9, 18, 25]. This holds especially true if a patient is screened for the first time and nothing is known about his/her former caries experience and risk/susceptibility.

**General recommendation 6:** Lesion activity assessment should include evaluation of quantity and quality of tooth surface biofilm before its removal, especially in plaque stagnation areas.

Level of evidence: –.

Level of agreement: 90% (agree,  $N = 18$ )/10% (neutral,  $N = 2$ ).

Inactive lesions usually do not require any additional interventional professional treatment unless for cosmetic or functional reasons. Active lesions need attention by both the oral healthcare professional team and the patient/caretaker, with either/both nonoperative or operative interventions. For this reason, documentation of lesion activity is vital in order to develop a personalized care plan.

**General recommendation 7:** During lesion charting, lesion activity status should be documented. This is especially true for lesions that have been/or will be treated using nonoperative preventive regimes, in order to monitor the treatment outcome.

Level of evidence: –.

Level of agreement: 80% (agree,  $N = 16$ )/20% (neutral,  $N = 4$ ).

### Pit and Fissure Caries and Coronal Smooth Surface Caries

The studies by Nyvad et al. [15] and Ekstrand et al. [9, 17] as well as a systematic review by Drancourt et al. [21], the ICCMS Guide [25], and the CariesCare practice guide [26] summarized valid criteria for caries lesions (Table 1).

**Recommendation 8:** Dental plaque and a matte/opaque/chalky white appearance of the enamel surface should be considered as indicators of active caries lesions. Plaque-free and shiny enamel should be considered as the characteristics of likely inactive non-cavitated enamel lesions.

Level of evidence: moderate.

Level of agreement: 95% (agree,  $N = 19$ )/5% (neutral,  $N = 1$ ).

**Recommendation 9:** Dental plaque and soft/leathery exposed dentine should be considered as indicators of active caries lesions, while plaque-free and shiny, hard exposed dentine should be considered as indicators of arrested/inactive lesions, and in the case of root caries also the proximity of the gingival margin.

Level of evidence: moderate.

Level of agreement: 90% (agree,  $N = 18$ )/10% (neutral,  $N = 2$ ).

The use of a ball-ended explorer or a periodontal probe is recommended in order to avoid further damage to the tooth surface. It was shown in earlier studies that a sharp-ended explorer, when used forcibly, is likely to damage dentine or carious enamel [29].



**Table 1.** Description of ICDAS criteria and criteria based on features for LAA

| ICDAS caries severity code | Description   | Clinical characteristics of caries lesions  |   |
|----------------------------|---|---|---|
|                            |   | active  | inactive  |
| 0                          | No or slight change in enamel translucency after prolonged air-drying (5 s)   |   |   |
| 1                          | First visual change in enamel (seen only after prolonged air-drying or restricted to within the confines of a pit or fissure) | Surface of enamel is whitish/yellowish opaque with a loss of luster; feels rough when the tip of the ball-ended probe is moved gently across the surface; lesion is in a plaque stagnation area | Surface of enamel is whitish, brownish, or black; enamel may be shiny and feels hard and smooth when the tip of the ball-ended probe is moved gently across the surface |
| 2                          | Distinct visual changes in enamel   |   |   |
| 3                          | Localized enamel breakdown in opaque or discolored enamel (without visual signs of dentinal involvement)                      |   |   |
| 4                          | Underlying dark shadow from dentine   | Probably active   |   |
| 5                          | Distinct cavity with visible dentine  | Cavity feels soft or leathery on gently probing the dentine   | Cavity may be shiny and feels hard on gently probing the dentine  |
| 6                          | Extensive distinct cavity with visible dentine (involving more than half the surface)   |   |   |

Based on ICDAS Committee [27] and Banerjee and Watson [28] and Drancourt et al. [21].

**Recommendation 10:** The hardness of dentine caries lesions should be assessed with a rounded dental explorer.

Level of evidence: –.

Level of agreement: 85% (agree, *N* = 17)/ 15% (neutral, *N* = 3).

### Proximal Caries

Proximal coronal caries is by nature less visible directly than occlusal pit and fissure caries because the lesions form beneath the proximal contact area. Thus, visual-tactile criteria can only be applied for those proximal lesions that are directly visible because of a missing adjacent tooth [30], because of gum recession in the older adult or in periodontally compromised patients, or because of tooth migration/rotation. Under normal circumstances, the adjacent tooth and gingival papilla hamper direct visual inspection and illumination of a proximal lesion. Thus, the remaining clinical characteristics (presence/quality/quantity of plaque, gingival bleeding) are the ones that clinicians must rely upon when performing proximal LAA. Ekstrand et al. [24] found that gingival bleeding after gentle probing was a better predictor for lesion progression in proximal cavitated lesions than the presence of plaque alone. Inter-

estingly, gingival bleeding is not part of the existing LAA systems and is rather regarded as a caries risk/susceptibility factor. Nevertheless, in a systematic review, Drancourt et al. [21] summarized that LAA of the whole tooth as well as of proximal surfaces using visual-tactile criteria give satisfactory outcomes.

**Recommendation 11:** In the presence of a proximal caries lesion, locally enhanced gingival bleeding provoked by gentle probing of the sulcus should be considered as an indicator for lesion activity.

Level of evidence: low.

Level of agreement: 75% (agree, *N* = 15)/20% (neutral, *N* = 4)/5% (disagree, *N* = 1).

### Root Caries

Several criteria have been suggested to judge root caries lesion activity (Table 2).

#### Visual Criteria

The presence of a remineralized superficial layer in arrested exposed root lesions has been verified histologically [36]. It was also reported that these lesions have a

smoother cross-sectional surface histologically when compared to non-remineralized lesions [36]. Clinically, a superficially remineralized and thus inactive root caries lesion looks shinier than an active root caries lesion. A root lesion that appears shiny is regarded as inactive; a root lesion that looks dull/matte/rough is considered to be active [17, 37]. A root lesion covered by a dense biofilm is regarded as active, a root lesion not covered by biofilm is regarded as inactive [18, 27]. While some authors propagate color as supportive for root caries LAA, there will be an overlap in degree of color assessed subjectively between clinicians. This might be attributable to the fact, that “mixed lesions” have been described, with parts of the lesion being more active, and parts being more inactive [16, 36]. Lynch and Beighton [31] did not find color to be predictive for root lesion activity. The distance of a root lesion from the gingival margin has been regarded as linked to lesion activity. However, the wording “usually close to the gingival margin” itself indicates, that there are individual subjective differences. The distance of a carious lesion from the gingival margin dictates the potential for improved oral hygiene, thus affecting lesion activity. However, it is dependent on patient factors (fluoride use, physical abilities, cognitive abilities, saliva quantity and quality, diet), whether or not a root lesion is and remains inactive when it is located above the gingival margin.

#### *Tactile Criteria*

The hardness of a root caries lesion is indicative of its mineral content. Inactive lesions show a higher degree of surface remineralization compared to active lesions. That is why they feel harder on gentle probing using a rounded dental explorer. The probing of the root caries is similar to probing coronal dentine lesions and should be gentle, using a dragging action across the surface as opposed to penetration of the surface per se (see Recommendation 9).

#### **Secondary Caries (CARS)**

In less accessible areas, such as cervical restoration or crown margins, tactile assessment is likely to be more relevant than visual assessment for lesion detection. In terms of LAA, however, an existing gap and its size alone seems to be neither indicative of continuing demineralization [38], nor for longevity of the tooth-restoration complex [39, 40]. Other factors such as cleansability, saliva quantity/quality/flow rate, or fluoride bioavailability all contribute to lesion activity. Thus, a gap next to a restoration should be regarded as one out of several risk factors, or as a predilection site. CARS or lesions around orthodontic brackets are to be regarded in their

activity assessment, the same as primary lesions. Thus, all clinical features that allow for LAA in primary lesions also are true for secondary carious lesions.

**Recommendation 12:** Lesion activity assessment for secondary lesions should be carried out similarly to primary caries lesions.

Level of evidence: –.

Level of agreement: 90% (agree,  $N = 18$ ) / 5% (neutral,  $N = 1$ ) / 5% (disagree,  $N = 1$ ).

#### **Caries Lesion Activity and Monitoring of Progression**

It has been outlined that a true validation of caries LAA should occur over time. Active lesions are more likely to receive operative intervention than inactive ones [15]. Similarly, the repeated step of lesion detection over time, i.e., repeated assessment of lesion depth and cavitation during recall appointments, gives a valid picture of the caries process dynamics. Besides assessing possible lesion progression, lesion monitoring also allows for checking the success and suitability of applied nonoperative preventive measures. The primary method of lesion detection is the visual-tactile method, and lesion progression should be documented in the patient’s record using a quantitative caries lesion detection system. For proximal sites, bitewing radiography is recommended for lesion detection, and thus an important and difficult question to answer deals with the suitable time intervals between bitewing radiographs. Clinicians have to balance between the diagnostic gain and the potential harmful effects of repeated ionizing radiation doses.

There is a plethora of national and international guidelines concerning the frequency of bitewing radiographs. Most of them differentiate two risk categories of patients (“low” and “high” caries risk), some operate on three categories (adding “moderate” or “extremely high”) [41]. As a rule of thumb, a greater risk of lesion progression justifies more frequent bitewing radiographs. For high caries risk/susceptible patients, an interval of 6–18 months has been proposed by several guidelines. For moderate to low caries risk patients, an interval of 12/24–48 months was suggested [41]. Interestingly, the most recent European Academy of Paediatric Dentistry (EAPD) best clinical practice guideline defines bitewing intervals depending on lesion presence and lesion depth instead of caries risk/susceptibility. Lesions at the enamel-dentine junction or beyond indicate an interval of 1–2 years, lesions



**Table 2.** Root caries activity criteria in the literature

| Method                     | Inactive  | Active   | References   |
|----------------------------|---|--|--|
| Visual appearance          | Shiny   | Dull/matte   | Nyvad et al. [15] (1999)<br>Ekstrand et al. [17] (2008)<br>Pitts et al. [25] (2014)                                |
|                            | Often not covered by biofilm<br>Distant from the gingival margin<br>Brownish or black | Typically, covered by biofilm<br>Usually close to the gingival margin<br>Yellowish, light-brown, or brownish | Nyvad et al. [15] (1999)<br>Nyvad et al. [15] (1999)<br>Nyvad et al. [15] (1999)<br>Lynch and Beighton [31] (1994) |
| Tactile                    | Smooth  | Rough  | Nyvad et al. [15] (1999)<br>Ekstrand et al. [17] (2008)<br>Pitts et al. [25] (2014)                                |
|                            | Hard  | Soft or sticky/leathery  | Nyvad et al. [15] (1999)<br>Ekstrand et al. [17] (2008)<br>Pitts et al. [25] (2014)                                |
| Fluorescence based methods | Different cutoffs   | Different cutoffs  | Zhang et al. [32] (2009)<br>Zhang et al. [33] (2016)   |
| QLF                        |   |  | Park et al. [34] (2022)  |
| Thermal imaging            | Cooling effect ( $\Delta Q$ ) <30 s   | Cooling effect ( $\Delta Q$ ) >30 s  | Yang et al. [35] (2020)  |

restricted to enamel an interval of 2–3 years, and “no lesion” justifies an interval of 5–10 years between two bitewing radiographs in children and adolescents [42]. It was furthermore clearly shown, that on a cohort level there is a risk of overtreatment through false positive findings when the caries prevalence is low and treatment decisions are based in bitewing radiographs [43]. Therefore, the indication to take bitewing radiographs or not should take into account several patient characteristics: age, lesion activity assessment, presence of dentine caries, presence of approximal contacts, and commitment or willingness to adhere to oral hygiene measures. It seems sensible to bear in mind some indisputable facts: (1) a patient’s caries lesion activity and, therefore, progression rate can change over time; (2) there are indications for bitewing radiographs or recall appointment intervals for other reasons than cariology (e.g., implant surveillance, periodontal health), and (3) patients are diagnosed and treated on an individual basis.

**Recommendation 13:** The recall intervals for visual and radiographic examination need to be adjusted to the presence of active caries lesions and recent caries progression rates. Modifications should be based on individual patient characteristics.

Level of evidence: low.

Level of agreement: 100% (agree,  $N = 20$ ).

## Conclusion

The expert panel has condensed external evidence and practical reasoning into clinical recommendations. Despite of missing high-level evidence, the results show that lesion activity assessment is a crucial part of the caries diagnostic and management process. It was pointed out how LAA can be carried out in the dental office, although the results indicate a somewhat heterogenous perception of LAA application.

## Conflict of Interest Statement

There is no conflict of interest.

## Funding Sources

All authors were supported by their institutions. No other funding sources were involved.

## Author Contributions

K.W. Neuhaus, C. Splieth, A. Banerjee, S. Martignon, D. Ricketts, F. Schwendicke, and M.H. van der Veen drafted the manuscript based on the reviews and statements discussed and voted on by K.W. Neuhaus, J. Kühnisch, A. Banerjee, S. Martignon, D. Ricketts, F. Schwendicke, M.H. van der Veen, S. Doméjean,

M. Fontana, A. Lussi, A. Jablonski-Momeni, F.M. Mendes, G. Douglas, G. Schmalz, G. Campus, J. Aps, K. Horner, N. Opdam, M.-C. Huysmans, and Ch. Splieth. K.W. Neuhaus, J. Kühnisch, A. Banerjee, S. Martignon, D. Ricketts, F. Schwendicke, M.H. van

der Veen, S. Doméjean, M. Fontana, A. Lussi, A. Jablonski-Momeni, F.M. Mendes, G. Douglas, G. Schmalz, G. Campus, J. Aps, K. Horner, N. Opdam, M.-C. Huysmans, and Ch. Splieth critically reviewed the manuscript.

## References

- 1 Banerjee A. Minimum intervention oral healthcare delivery: is there consensus? *Br Dent J.* 2020;229(7):393–5. <https://doi.org/10.1038/s41415-020-2235-x>
- 2 Machiulskiene V, Campus G, Carvalho JC, Dige I, Ekstrand KR, Jablonski-Momeni A, et al. Terminology of dental caries and dental caries management: consensus report of a workshop organized by ORCA and Cariology Research Group of IADR. *Caries Res.* 2020;54(1):7–14. <https://doi.org/10.1159/000503309>
- 3 Meyer-Lueckel H, Machiulskiene V, Giacomani RA. How to intervene in the root caries process? Systematic review and meta-analyses. *Caries Res.* 2019;53(6):599–608. <https://doi.org/10.1159/000501588>
- 4 Paris S, Banerjee A, Bottenberg P, Breschi L, Campus G, Domejean S, et al. How to intervene in the caries process in older adults: a joint ORCA and EFCD expert Delphi consensus statement. *Caries Res.* 2020;54(5–6):1–7. <https://doi.org/10.1159/000510843>
- 5 Santamaria RM, Abudrya MH, Gul G, Mourad MS, Gomez GF, Zandona AGF. How to intervene in the caries process: dentin caries in primary teeth. *Caries Res.* 2020;54(4):306–23. <https://doi.org/10.1159/000508899>
- 6 Schmoekel J, Gorseta K, Splieth CH, Juric H. How to intervene in the caries process in children: a systematic review. *Caries Res.* 2020;54(2):102–12. <https://doi.org/10.1159/000504335>
- 7 Schwendicke F, Splieth CH, Bottenberg P, Breschi L, Campus G, Domejean S, et al. How to intervene in the caries process in adults: proximal and secondary caries? An EFCD-ORCA-DGZ expert Delphi consensus statement. *Clin Oral Investig.* 2020; 24(9):3315–21. <https://doi.org/10.1007/s00784-020-03431-0>
- 8 Splieth CH, Banerjee A, Bottenberg P, Breschi L, Campus G, Ekstrand KR, et al. How to intervene in the caries process in children: a joint ORCA and EFCD expert Delphi consensus statement. *Caries Res.* 2020;54(4): 297–305. <https://doi.org/10.1159/000507692>
- 9 Ekstrand KR, Martignon S, Ricketts DJ, Qvist V. Detection and activity assessment of primary coronal caries lesions: a methodologic study. *Oper Dent.* 2007;32(3):225–35. <https://doi.org/10.2341/06-63>
- 10 Thylstrup A, Bruun C, Holmen L. In vivo caries models: mechanisms for caries initiation and arrestment. *Adv Dent Res.* 1994;8(2):144–57. <https://doi.org/10.1177/08959374940080020401>
- 11 Schmid B, Fischeder D, Arndt S, Häberlein I. Site-specific detection of lactic acid production on tooth surfaces. *Caries Res.* 2002; 36:217.
- 12 Splieth C, Bernhardt O. Prediction of caries development for molar fissures with semi-quantitative mutans streptococci test. *Eur J Oral Sci.* 1999;107(3):164–9. <https://doi.org/10.1046/j.0909-8836.1999.eos1070302.x>
- 13 Carvalho JC, Ekstrand KR, Thylstrup A. Dental plaque and caries on occlusal surfaces of first permanent molars in relation to stage of eruption. *J Dent Res.* 1989;68(5):773–9. <https://doi.org/10.1177/00220345890680050401>
- 14 Ekstrand KR, Ricketts DN, Kidd EA, Qvist V, Schou S. Detection, diagnosing, monitoring and logical treatment of occlusal caries in relation to lesion activity and severity: an in vivo examination with histological validation. *Caries Res.* 1998;32(4):247–54. <https://doi.org/10.1159/000016460>
- 15 Nyvad B, Machiulskiene V, Baelum V. Reliability of a new caries diagnostic system differentiating between active and inactive caries lesions. *Caries Res.* 1999;33(4):252–60. <https://doi.org/10.1159/000016526>
- 16 Nyvad B, Machiulskiene V, Baelum V. Construct and predictive validity of clinical caries diagnostic criteria assessing lesion activity. *J Dent Res.* 2003;82(2):117–22. <https://doi.org/10.1177/154405910308200208>
- 17 Ekstrand K, Martignon S, Holm-Pedersen P. Development and evaluation of two root caries controlling programmes for home-based frail people older than 75 years. *Gerodontology.* 2008;25(2):67–75. <https://doi.org/10.1111/j.1741-2358.2007.00200.x>
- 18 Ismail AI, Pitts NB, Tellez M; Authors of International Caries Classification and Management System ICCMS, Banerjee A, Deery C, et al. The international caries classification and management system (ICCMS) an example of a caries management pathway. *BMC Oral Health.* 2015;15 Suppl 1(Suppl 1):S9. <https://doi.org/10.1186/1472-6831-15-S1-S9>
- 19 Carvalho JC, Mestrinho HD, Oliveira LS, Varjao MM, Aimee N, Qvist V. Validation of the visible occlusal plaque index (VOPI) in estimating caries lesion activity. *J Dent.* 2017; 64:37–44. <https://doi.org/10.1016/j.jdent.2017.06.003>
- 20 Nyvad B, Baelum V. Nyvad criteria for caries lesion activity and severity assessment: a validated approach for clinical management and Research. *Caries Res.* 2018;52(5): 397–405. <https://doi.org/10.1159/000480522>
- 21 Drancourt N, Roger-Leroi V, Martignon S, Jablonski-Momeni A, Pitts N, Domejean S. Carious lesion activity assessment in clinical practice: a systematic review. *Clin Oral Investig.* 2019;23(4):1513–24. <https://doi.org/10.1007/s00784-019-02839-7>
- 22 Kühnisch J, Aps JKM, Splieth C, Lussi A, Jablonski-Momeni A, Mendes FM, et al. ORCA-EFCD consensus report on clinical recommendation for caries diagnosis. Paper I: caries lesion detection and depth assessment. *Clin Oral Investig.* 2024;28(4):227. <https://doi.org/10.1007/s00784-024-05597-3>
- 23 Huysmans MC, Fontana M, Lussi A, Jablonski-Momeni A, Banerjee A, Ricketts D, et al. Recommendations on caries diagnosis at the individual level. An ORCA/EFCD consensus document. *Caries Res.* 2024.
- 24 Ekstrand KR, Bruun G, Bruun M. Plaque and gingival status as indicators for caries progression on approximal surfaces. *Caries Res.* 1998; 32(1):41–5. <https://doi.org/10.1159/000016428>
- 25 Pitts NB, Ismail AI, Martignon S, Ekstrand KR, Douglas GVA, Longbottom C. ICCMS™ guide for practitioners and educators. 2014.
- 26 Martignon S, Pitts NB, Goffin G, Mazevet M, Douglas GVA, Newton JT, et al. CariesCare practice guide: consensus on evidence into practice. *Br Dent J.* 2019;227(5):353–62. <https://doi.org/10.1038/s41415-019-0678-8>
- 27 ICDAS Committee. Criteria manual– International Caries Detection and Assessment System (ICDAS II). Scotland: dental health services Research unit. 2005.
- 28 Banerjee A, Watson TF. Pickard’s guide to minimally invasive dentistry. Oxford University Press; 2010.
- 29 Neuhaus KW, Ellwood R, Lussi A, Pitts NB. Traditional lesion detection aids. *Monogr Oral Sci.* 2009;21:42–51. <https://doi.org/10.1159/000224211>
- 30 Ekstrand KR, Luna LE, Promisiero L, Cortes A, Cuevas S, Reyes JF, et al. The reliability and accuracy of two methods for proximal caries detection and depth on directly visible proximal surfaces: an in vitro study. *Caries Res.* 2011; 45(2):93–9. <https://doi.org/10.1159/000324439>
- 31 Lynch E, Beighton D. A comparison of primary root caries lesions classified according to colour. *Caries Res.* 1994;28(4):233–9. <https://doi.org/10.1159/000261971>
- 32 Zhang W, McGrath C, Lo EC. A comparison of root caries diagnosis based on visual-tactile criteria and DIAGNOdent in vivo. *J Dent.* 2009;37(7):509–13. <https://doi.org/10.1016/j.jdent.2009.03.009>

- 33 Zhang W, McGrath C, Lo ECM. Effectiveness of DIAGNOdent in detecting root caries without dental scaling among community-dwelling elderly. *Oral Health Prev Dent*. 2016;14(6):555–61. <https://doi.org/10.3290/j.ohpd.a37140>
- 34 Park KJ, Meissner T, Gunther E, Schmalz G, Kottmann T, Krause F, et al. Arrest of root caries with an adjuvant chlorhexidine-fluoride varnish over a 12-months observation period: a QLF-analyzed, placebo-controlled, randomized, clinical trial (RCT). *Odontology*. 2022;110(1):193–202. <https://doi.org/10.1007/s10266-021-00637-w>
- 35 Yang V, Zhu Y, Curtis D, Le O, Chang NYN, Fried WA, et al. Thermal imaging of root caries in vivo. *J Dent Res*. 2020;99(13):1502–8. <https://doi.org/10.1177/0022034520951157>
- 36 Carvalho TS, Lussi A. Assessment of root caries lesion activity and its histopathological features. *Monogr Oral Sci*. 2017;26:63–9. <https://doi.org/10.1159/000479346>
- 37 Christensen LB, Bardow A, Ekstrand K, Fiehn NE, Heitmann BL, Qvist V, et al. Root caries, root surface restorations and lifestyle factors in adult Danes. *Acta Odontol Scand*. 2015;73(6):467–73. <https://doi.org/10.3109/00016357.2014.986753>
- 38 Cenci MS, Pereira-Cenci T, Cury JA, Ten Cate JM. Relationship between gap size and dentine secondary caries formation assessed in a microcosm biofilm model. *Caries Res*. 2009;43(2):97–102. <https://doi.org/10.1159/000209341>
- 39 Kidd EA, O'Hara JW. The caries status of occlusal amalgam restorations with marginal defects. *J Dent Res*. 1990;69(6):1275–7. <https://doi.org/10.1177/00220345900690061001>
- 40 Wilson N, Lynch CD, Brunton PA, Hickel R, Meyer-Lueckel H, Gurgan S, et al. Criteria for the replacement of restorations: Academy of operative dentistry European section. *Oper Dent*. 2016;41(S7):S48–S57. <https://doi.org/10.2341/15-058-O>
- 41 Goodwin TL, Devlin H, Glenny AM, O'Malley L, Horner K. Guidelines on the timing and frequency of bitewing radiography: a systematic review. *Br Dent J*. 2017;222(7):519–26. <https://doi.org/10.1038/sj.bdj.2017.314>
- 42 Kuhnisch J, Anttonen V, Duggal MS, Spyridonos ML, Rajasekharan S, Sobczak M, et al. Best clinical practice guidance for prescribing dental radiographs in children and adolescents: an EAPD policy document. *Eur Arch Paediatr Dent*. 2020;21(4):375–86. <https://doi.org/10.1007/s40368-019-00493-x>
- 43 Baelum V. What is an appropriate caries diagnosis? *Acta Odontol Scand*. 2010;68(2):65–79. <https://doi.org/10.3109/00016350903530786>