



**HAL**  
open science

# Arthroscopic Latarjet yields better union and prevention of instability compared to arthroscopic bony Bankart repair in shoulders with recurrent anterior instability: a systematic review

Anselme Billaud, Laurent Baverel, Pierre Metais, Floris van Rooij, Ankitha Kumble, Guillaume Villatte, Edouard Dejour, Geoffroy Nourissat

## ► To cite this version:

Anselme Billaud, Laurent Baverel, Pierre Metais, Floris van Rooij, Ankitha Kumble, et al.. Arthroscopic Latarjet yields better union and prevention of instability compared to arthroscopic bony Bankart repair in shoulders with recurrent anterior instability: a systematic review. *Knee Surgery, Sports Traumatology, Arthroscopy*, 2023, 31 (12), pp.5994-6005. 10.1007/s00167-023-07655-x . hal-04611204

**HAL Id: hal-04611204**

**<https://uca.hal.science/hal-04611204v1>**

Submitted on 13 Jun 2024

**HAL** is a multi-disciplinary open access archive for the deposit and dissemination of scientific research documents, whether they are published or not. The documents may come from teaching and research institutions in France or abroad, or from public or private research centers.

L'archive ouverte pluridisciplinaire **HAL**, est destinée au dépôt et à la diffusion de documents scientifiques de niveau recherche, publiés ou non, émanant des établissements d'enseignement et de recherche français ou étrangers, des laboratoires publics ou privés.



Distributed under a Creative Commons Attribution 4.0 International License

1 **Title:** Arthroscopic Latarjet yields better union and prevention of instability compared to  
2 arthroscopic bankart repairs in shoulders with recurrent anterior instability: a systematic  
3 review

#### 4 **Abstract**

5 **Purpose:** To determine whether arthroscopic Latarjet procedure arthroscopic Latarjet or  
6 arthroscopic bony Bankart repair arthroscopic bony Bankart repair provide better outcomes in  
7 terms of rates of recurrent instability, non-union and complications, as well as clinical scores  
8 and range of motion.

9 **Methods:** An electronic literature search was performed using PubMed, Embase®, and  
10 Cochrane databases, applying the following keywords: “Arthroscopic bony bankart” OR  
11 “Arthroscopic osseous bankart” AND “Arthroscopic Latarjet” OR “Arthroscopic coracoid  
12 Bone block”.

13 **Results:** The systematic search returned 1,465 records, of which 29 were included  
14 (arthroscopic bony Bankart repair, n=16; arthroscopic Latarjet, n=13). 37 datasets were  
15 included for data extraction, on 1483 shoulders. Compared to arthroscopic Latarjet,  
16 arthroscopic bony Bankart repair had significantly higher instability rates (0.14; CI, 0.10–  
17 0.18; vs 0.04; CI, 0.02–0.06), significantly lower union rates (0.63; CI, 0.28–0.91 vs 0.98; CI,  
18 0.93–1.00), and significantly lower pain on VAS (0.42; CI, 0.17–0.67 vs 1.17; CI, 0.96–  
19 1.38). There were no significant differences in preoperative glenoid bone loss, follow-up,  
20 complication rate, ROWE score, ASES score, external rotation, and anterior forward  
21 elevation between arthroscopic Latarjet and arthroscopic bony Bankart repair.

22 **Conclusion:** Compared to arthroscopic Latarjet, arthroscopic bony Bankart repair results in  
23 significantly (i) higher rates of recurrent instability (14% vs 4%), (ii) lower union rates (63%  
24 vs 98%), but (iii) slightly lower pain on VAS (0.45 vs 1.17). There were no differences in  
25 complication rates, clinical scores, or postoperative ranges of motion.

26 **Level of Evidence:** Level IV

27 **Keywords:** Arthroscopic Latarjet procedure, bony Bankart procedure, anterior instability,  
28 outcomes

29 **Introduction**

30 Anterior shoulder instability often requires surgical treatment, particularly in young athletes  
31 who wish to resume sports [3,46,50]. The most common surgical treatments involve either  
32 labral or capsular repair in shoulders with no glenoid defects [34,51], or bone-block  
33 procedures in shoulders with glenoid defects [13,26,35]. The Latarjet technique is among the  
34 most popular bone-block procedures, as it proved effective at preventing recurrent  
35 dislocations [1,2,12,21,25,27,39] whether performed as an open or an arthroscopic procedure  
36 [15,33]. The Latarjet technique is however technically demanding and therefore has a  
37 considerable learning curve and requires alteration of native scapular anatomy [5,9,15].

38

39 More recently, arthroscopic bony Bankart repair arthroscopic bony Bankart repair[49] was  
40 introduced as a less invasive alternative to arthroscopic Latarjet, to treat anterior shoulder  
41 instability with traumatic glenoid defects, where the bone fragment is still present and could  
42 be sutured back onto the glenoid [4]. While arthroscopic bony Bankart repair demonstrated  
43 satisfactory bone union rates, it is associated with higher rates of recurrent instability  
44 compared to arthroscopic Latarjet [6,39,52,54], and may be insufficient to treat shoulders  
45 with irreparable ligamentous damage, attritional glenoid bone loss, or major bone  
46 deficiencies [15].

47

48 There is no consensus on the optimal treatment for recurrent anterior shoulder instability with  
49 traumatic glenoid defects. Therefore, the purpose of this study is to determine whether  
50 arthroscopic Latarjet or arthroscopic bony Bankart repair provide better outcomes for this  
51 population in terms of rates of recurrent instability, non-union and complications, as well as  
52 clinical scores and range of motion.

53 **Materials and Methods**

54 The protocol for this systematic review was submitted to PROSPERO prior to  
55 commencement (registration number BLINDED) and conforms to the principles outlined in  
56 the handbook of the Cochrane Collaboration [19], along with the guidelines established by  
57 the Preferred Reporting Items for Systematic Reviews and Meta-analysis (PRISMA) [37].

58

59 *Search strategy*

60 The authors conducted a structured electronic literature search on 06 July 2022 using the  
61 PubMed, Embase®, and Cochrane Central Register of Controlled Trials databases, applying  
62 the following keywords: “Arthroscopic bony bankart” OR “Arthroscopic osseous bankart”  
63 AND “Arthroscopic Latarjet” OR “Arthroscopic coracoid Bone block”. The full search  
64 strategy is presented in Appendix I. The search was limited to articles published between  
65 2002 and 2022. After removal of duplicate records, each of two researchers (BLINDED)  
66 screened the titles and abstracts to determine the suitability for the review using the following  
67 predefined eligibility criteria:

68

69 *Inclusion criteria*

- 70 - Comparative or non-comparative studies on patients with recurrent anterior shoulder  
71 instability that underwent either primary arthroscopic Latarjet or primary arthroscopic  
72 bony Bankart repair with or without adjuvant procedures
- 73 - Studies that measured preoperative glenoid bone loss using computed tomography  
74 (CT) scans
- 75 - Studies that report pre- and post-operative clinical outcomes in terms of, recurrence of  
76 instability, non-union, complication rates, range of motion, or clinical scores

77

78 *Exclusion criteria:*

- 79 - Narrative or systematic reviews, case reports, expert opinions, editorials, letters to  
80 editors, computer simulations, cadaver or laboratory studies
- 81 - Studies published in languages other than English, French, German, Italian, Spanish,  
82 and Dutch to avoid translation errors.

83

84 *Study selection*

85 Studies that met the eligibility criteria during title and abstract screening underwent full-text  
86 screening by two researchers (BLINDED) and any disagreement was first discussed between  
87 the researchers, and if required, a third researcher (BLINDED) resolved any disagreement.  
88 The reference lists of studies for full text review were searched, and an expert (BLINDED)  
89 was consulted to identify further relevant studies that may not have been captured by the  
90 database searches.

91

92 *Data extraction and quality assessment*

93 Data extraction was performed by two researchers (BLINDED) independently and their  
94 results were compared to ensure accuracy. Where there was disagreement in the documented  
95 value, the true value was ascertained by simultaneous review of the data in question by both  
96 researchers. The following information was extracted from the included studies; author(s),  
97 journal, year of publication, level of evidence, country where study was performed, conflicts  
98 of interest and funding declaration. Furthermore, the following clinical data was extracted:  
99 type of surgery, subgroup size, sex, age, preoperative glenoid bone loss, union rates (instead  
100 of non-union rates which were inconsistently defined and reported), recurrent instability rates  
101 (defined as recurrence of subluxation and/or dislocation), post-operative complication rates,

102 range of motion (ROM; ER1, arm at 0° of abduction; ER2, arm at 90° of abduction; AFE,  
103 anterior forward elevation), clinical scores, and pain on VAS scale.

104

105 Methodological quality of the eligible studies was assessed by two researchers (BLINDED)  
106 according to the Joanna Briggs Institute (JBI) checklist, to appraise the reporting quality (10  
107 items). Where there was disagreement between the researchers, consensus was achieved by  
108 discussion and review.

109

#### 110 *Statistical analysis*

111 When available in the original articles, outcomes were tabulated: continuous outcomes were  
112 reported as means, standard deviations, and ranges, while categorical outcomes were reported  
113 as proportions. Pooled estimates were calculated if mean and standard deviations were  
114 available for least 3 studies reported. When the standard deviation was not reported, the range  
115 was used to calculate standard deviation using a method outlined by Hozo et al.[22].  
116 Heterogeneity was evaluated by visual inspection of forest plots and using the  $I^2$  statistic and  
117 its connected  $\chi^2$  test, to provide a measure of the degree of inconsistency across studies.  
118 Pooled estimates of raw means and their 95% confidence interval (CI) were calculated using  
119 a random-effects model framework. Pooled estimates of proportions and their 95%  
120 confidence intervals (CI) were calculated via Freeman-Tukey double arcsine transformation  
121 using inverse-variance weighting within a random-effects model framework. P-values <0.05  
122 were considered statistically significant. Statistical analyses were performed using R version  
123 4.1.3 (R Foundation for Statistical Computing, Vienna, Austria) using the meta package.

## 124 **Results**

125 The systematic search returned 1,465 records, of which 563 were duplicates, leaving 902 for  
126 title and abstract screening (Figure 1). A total of 786 studies were excluded by examining  
127 their titles and/or abstracts because: 500 were not relevant, 223 were editorials/conference  
128 proceedings etc., 29 were reviews, 17 were published before 2002, and 17 were published in  
129 languages other than those defined in the exclusion criteria. A further 87 studies were  
130 excluded after full-text review. This left 29 eligible studies,[1,7,8,11,14,16-18,23,24,29-  
131 32,38,40-45,47,48,53,55-59] of which 16 assessed arthroscopic bony Bankart repair, 13  
132 assessed arthroscopic Latarjet (Table 1 and 2). All studies reported preoperative glenoid bone  
133 loss: 21 reported mean preoperative glenoid bone loss, of which 4 created subgroups of  
134 glenoid bone loss and reported the mean loss of each subgroup, while 8 used a threshold of  
135 glenoid bone loss as a part of their inclusion criteria. Of the 29 eligible studies, 37 datasets  
136 were included for data extraction, with a total of 1,483 shoulders (arthroscopic bony Bankart  
137 repair, n=874; AL, n=609) (Table 3 and 4). Of the 37 included datasets, 12 datasets reported  
138 on concomitant Hill-Sachs (arthroscopic bony Bankart repair, n=7 and arthroscopic Latarjet,  
139 n=5) lesions.

140

### 141 *Quality assessment*

142 Of the 29 eligible studies, 2 were prospective and 27 were retrospective. Of the 29 studies, 3  
143 did not report criteria for inclusion and 2 did not specify the presenting sites demographic  
144 information. Furthermore, it was unclear in 4 studies whether the study had complete  
145 inclusion of participants. Overall, all included studies had good to excellent scores according  
146 to the JBI checklist (Table 5).

147

### 148 *Preoperative glenoid bone loss*



149 Of the 37 included datasets, preoperative glenoid bone loss was reported as part of their  
150 inclusion criteria in 7 and was reported as a mean in 26 datasets (arthroscopic bony Bankart  
151 repair, n=19; arthroscopic Latarjet, n=7). There was no significant difference in mean  
152 preoperative glenoid bone loss between shoulders treated by arthroscopic bony Bankart repair  
153 (17.6%; CI, 13.7–21.6;  $I^2=99%$ ) or arthroscopic Latarjet (18.9%; CI, 13.5–24.3;  $I^2=98%$ )  
154 (Figure 2).

155

#### 156 *Follow-up*

157 Of the 37 included datasets, mean follow-up was reported in 24 (arthroscopic bony Bankart  
158 repair, n=13; arthroscopic Latarjet, n=11). There was no significant difference in mean  
159 follow-up between shoulders treated by arthroscopic bony Bankart repair (49.3 months; CI,  
160 27.9–70.8;  $I^2=100%$ ) or arthroscopic Latarjet (29 months; CI, 20.7– 37.3;  $I^2=99%$ ).

161

#### 162 *Recurrent instability*

163 Of the 37 included datasets, rates of recurrent instability were reported in 19 (arthroscopic  
164 bony Bankart repair, n=13; arthroscopic Latarjet, n=6). There was a statistically significant  
165 higher rate of instability following arthroscopic bony Bankart repair (0.14; CI, 0.10–0.18;  
166  $I^2=49%$ ) compared to arthroscopic Latarjet (0.04; CI, 0.02–0.06;  $I^2=0%$ ) (Figure 3).

167

#### 168 *Union*

169 Of the 37 included datasets, union was reported in 14 (arthroscopic bony Bankart repair, n=5;  
170 arthroscopic Latarjet, n=9). All studies assessed union using postoperative CT scans, and  
171 there was a statistically significant lower union rate following arthroscopic bony Bankart  
172 repair (0.63; CI, 0.28–0.91;  $I^2=96%$ ) compared to arthroscopic Latarjet (0.98; CI, 0.93–1.00;  
173  $I^2=70%$ ) (Figure 4).

174

175 *Postoperative complications*

176 Of the 37 included datasets, complication rates were reported in 15 (arthroscopic bony  
177 Bankart repair, n=3; arthroscopic Latarjet, n=12), of which 3 reported rates instead of  
178 absolute values [23,57]. There was no statistical difference in complication rate following  
179 arthroscopic bony Bankart repair (0.01; CI, 0.00–0.07;  $I^2=0\%$ ) compared to arthroscopic  
180 Latarjet (0.03; CI, 0.00–0.06;  $I^2=47\%$ ) (Figure 5).

181

182 *Clinical scores*

183 There were no significant differences between arthroscopic bony Bankart repair and  
184 arthroscopic Latarjet, in terms of ROWE score (92.78 vs 92.47), and ASES score (94.26 vs  
185 92.16). However, arthroscopic bony Bankart repair demonstrated significantly lower pain on  
186 VAS (0.42) compared to arthroscopic Latarjet (1.17;  $p<0.01$ ).

187

188 *Range of motion*

189 There were no significant differences between arthroscopic bony Bankart repair and  
190 arthroscopic Latarjet, in terms of ER1 ( $59.5^\circ$  vs  $57.26^\circ$ ), and AFE ( $167.93^\circ$  vs  $170.90^\circ$ ).

191 **Discussion**

192 The most important findings of this meta-analysis are that, compared to arthroscopic Latarjet,  
193 arthroscopic bony Bankart repair results in significantly (i) higher rates of recurrent  
194 instability (14% vs 4%), (ii) lower union rates (63% vs 98%), but (iii) slightly lower pain on  
195 VAS (0.45 vs 1.17). There were however no significant differences in complication rates,  
196 clinical scores, or postoperative ranges of motion. The null hypothesis that the two  
197 procedures would result in comparable outcomes is therefore refuted. The clinical relevance  
198 of these findings is that, while arthroscopic bony Bankart repair demonstrated comparable  
199 clinical scores to arthroscopic Latarjet, the latter might be more suitable in patients prone to  
200 recurrent instability or non-union. It is worth noting, however, that the present meta-analysis  
201 did not account for the surgeon experience and learning curves, which should also be  
202 considered when choosing the surgical technique.

203

204 The present systematic review included studies that had good to excellent scores according to  
205 the JBI checklist. A previous systematic review by Longo et al.[36] compared outcomes of all  
206 surgical treatments for traumatic anterior glenohumeral instability with glenoid and/or  
207 humeral bony defects. Longo et al.[36] found that shoulders with glenoid bone loss <25%  
208 were most frequently treated with arthroscopic Bankart repair (50%) or arthroscopic bony  
209 Bankart repair (32%), while shoulders with glenoid bone loss >25% were most frequently  
210 managed by open reconstruction with bone graft (37%), arthroscopic Bristow procedure  
211 (26%), or open Latarjet procedure (OLP) (22%). The present meta-analysis found no  
212 significant difference in mean preoperative glenoid bone loss between shoulders treated with  
213 arthroscopic bony Bankart repair (17.6%; CI, 13.7–21.6) versus arthroscopic Latarjet (18.9%;  
214 CI, 13.5–24.3). However, it remains unclear whether the choice of procedure should be based  
215 on the extent of glenoid bone loss, or rather on the size of the remaining bone fragment

216 present that could be sutured back onto the glenoid. It is worth noting that arthroscopic bony  
217 Bankart repair may be insufficient to treat shoulders with irreparable ligamentous damage,  
218 attritional glenoid bone loss, or major bone deficiencies [15], where bone block procedures  
219 may be the only treatment option. A recent systematic review by Hurley et al.[28] compared  
220 outcomes of ABR alone versus ABR with remplissage versus OLP, to treat anterior shoulder  
221 instability in patients with concomitant Hill-Sachs lesions. Hurley et al.[28] found higher  
222 rates of recurrent instability following ABR alone (16.8%) compared to OLP (7.0%) and  
223 ABR with remplissage (3.2%). A study by Horinek et al. [20] compared OLP with ABR with  
224 remplissage, for anterior shoulder instability and found no difference in terms of clinical  
225 scores, return to sport, and satisfaction. In the present meta-analysis, only one study  
226 performed arthroscopic bony Bankart repair with remplissage (in 11 of 312 patients) [47] but  
227 did not report the outcomes of this subgroup. Furthermore, out of the 29 included studies in  
228 the present meta-analysis, Hill-Sachs lesions were reported in 15 studies, and their prevalence  
229 ranged from 24% to 100%. It was not possible to perform a subgroup analysis of the  
230 outcomes of this pathology as the type of Hill-Sachs lesion was not consistently reported,  
231 which could affect the rate of recurrent instability [10,36].

232

233 The results of the present meta-analysis should be interpreted with the following limitations  
234 in mind. All included studies were case series, although the level of quality was good to fair.  
235 Furthermore, the thresholds of glenoid bone loss reported were heterogenous across studies  
236 which makes it difficult to determine whether the choice for arthroscopic bony Bankart repair  
237 or arthroscopic Latarjet should be based on the extent of preoperative glenoid bone loss. This  
238 meta-analysis did not evaluate Hill-Sachs lesions which could have affected recurrent  
239 instability rates [10,36] as the specific lesions were not consistently reported. Additionally,  
240 there is need for a more standardised method of reporting outcomes as a great number of

241 different clinical scores were reported, making it difficult to quantitatively compare studies.  
242 Finally, it is worth noting that, while there was no statistically significant difference in  
243 follow-up between the two techniques, the mean follow-up for arthroscopic bony Bankart  
244 repair was almost 2 years longer than for arthroscopic Latarjet, which could introduce bias in  
245 the comparisons.

246

#### 247 *Conclusion*

248 This systematic review and meta-analysis found that, compared to arthroscopic Latarjet,  
249 arthroscopic bony Bankart repair results in significantly (i) higher rates of recurrent  
250 instability (14% vs 4%), (ii) lower union rates (63% vs 98%), but (iii) slightly lower pain on  
251 VAS (0.45 vs 1.17). There were however no significant differences in complication rates,  
252 clinical scores, or postoperative ranges of motion.

- 254 1. Ali J, Altintas B, Pulatkan A, Boykin RE, Aksoy DO, Bilsel K (2020) Open Versus  
255 Arthroscopic Latarjet Procedure for the Treatment of Chronic Anterior Glenohumeral  
256 Instability With Glenoid Bone Loss. *Arthroscopy* 36 (4):940-949.
- 257 2. Ali ZS, Hurley ET, Jamal MS, Horan MP, Montgomery C, Pauzenberger L, Millett  
258 PJ, Mullett H (2021) Low rate of recurrent instability following the open Latarjet  
259 procedure as a revision procedure for failed prior stabilization surgery. *Knee Surg  
260 Sports Traumatol Arthrosc* 29 (7):2110-2117.
- 261 3. Baverel L, Colle PE, Saffarini M, Anthony Odri G, Barth J (2018) Open Latarjet  
262 Procedures Produce Better Outcomes in Competitive Athletes Compared With  
263 Recreational Athletes: A Clinical Comparative Study of 106 Athletes Aged Under 30  
264 Years. *Am J Sports Med* 46 (6):1408-1415.
- 265 4. Bedi A, Ryu RK (2009) The treatment of primary anterior shoulder dislocations. *Instr  
266 Course Lect* 58:293-304.
- 267 5. Bockmann B, Nebelung W, Gröger F, Leuzinger J, Agneskirchner J, Brunner U,  
268 Seybold D, Streich J, Bartsch S, Schicktanz K, Maier D, Königshausen M, Patzer T,  
269 Venjakob AJ (2023) The arthroscopic treatment of anterior shoulder instability with  
270 glenoid bone loss shows similar clinical results after Latarjet procedure and iliac crest  
271 autograft transfer. *Knee Surg Sports Traumatol Arthrosc* 31 (10):4566-4574.
- 272 6. Bohu Y, Abadie P, van Rooij F, Nover L, Berhouet J, Hardy A (2021) Latarjet  
273 procedure enables 73% to return to play within 8 months depending on preoperative  
274 SIRSI and Rowe scores. *Knee Surg Sports Traumatol Arthrosc* 29 (8):2606-2615.
- 275 7. Boileau P, Saliken D, Gendre P, Seeto BL, d'Ollonne T, Gonzalez JF, Bronsard N  
276 (2019) Arthroscopic Latarjet: Suture-Button Fixation Is a Safe and Reliable  
277 Alternative to Screw Fixation. *Arthroscopy* 35 (4):1050-1061.
- 278 8. Bonneville N, Girard M, Dalmas Y, Martinel V, Faruch M, Mansat P (2021) Short-  
279 Term Bone Fusion With Arthroscopic Double-Button Latarjet Versus Open-Screw  
280 Latarjet. *Am J Sports Med* 49 (6):1596-1603.
- 281 9. Buda M, D'Ambrosi R, Bellato E, Blonna D, Cappellari A, Delle Rose G, Merolla G,  
282 Committee SIR (2021) Failed Latarjet procedure: a systematic review of surgery  
283 revision options. *J Orthop Traumatol* 22 (1):24.
- 284 10. Calandra JJ, Baker CL, Uribe J (1989) The incidence of Hill-Sachs lesions in initial  
285 anterior shoulder dislocations. *Arthroscopy* 5 (4):254-257.
- 286 11. Calvo C, Calvo J, Rojas D, Valencia M, Calvo E (2021) Clinical Relevance of  
287 Persistent Off-Track Hill-Sachs Lesion After Arthroscopic Latarjet Procedure. *Am J  
288 Sports Med* 49 (8):2006-2012.

- 289 12. Cerciello S, Corona K, Morris BJ, Santagada DA, Maccauro G (2019) Early  
290 Outcomes and Perioperative Complications of the Arthroscopic Latarjet Procedure:  
291 Systematic Review and Meta-analysis. *Am J Sports Med* 47 (9):2232-2241.
- 292 13. Chillemi C, Guerrisi M, Paglialunga C, Salate Santone F, Osimani M (2021) Latarjet  
293 procedure for anterior shoulder instability: a 24-year follow-up study. *Arch Orthop  
294 Trauma Surg* 141 (2):189-196.
- 295 14. Dumont GD, Fogerty S, Rosso C, Lafosse L (2014) The arthroscopic latarjet  
296 procedure for anterior shoulder instability: 5-year minimum follow-up. *Am J Sports  
297 Med* 42 (11):2560-2566.
- 298 15. From the American Association of Neurological Surgeons ASoNC, Interventional  
299 Radiology Society of Europe CIRACoNSESOMINTESoNESOSfCA, Interventions  
300 SoIRSoNS, World Stroke O, Sacks D, Baxter B, Campbell BCV, Carpenter JS,  
301 Cognard C, Dippel D, Eesa M, Fischer U, Hausegger K, Hirsch JA, Shazam Hussain  
302 M, Jansen O, Jayaraman MV, Khalessi AA, Kluck BW, Lavine S, Meyers PM,  
303 Ramee S, Rufenacht DA, Schirmer CM, Vorwerk D (2018) Multisociety Consensus  
304 Quality Improvement Revised Consensus Statement for Endovascular Therapy of  
305 Acute Ischemic Stroke. *Int J Stroke* 13 (6):612-632.
- 306 16. Giacomo GD, Pugliese M, Peebles AM, Provencher MT (2022) Bone Fragment  
307 Resorption and Clinical Outcomes of Traumatic Bony Bankart Lesion Treated With  
308 Arthroscopic Repair Versus Open Latarjet. *Am J Sports Med* 50 (5):1336-1343.
- 309 17. Godin JA, Altintas B, Horan MP, Hussain ZB, Pogorzelski J, Fritz EM, Millett PJ  
310 (2019) Midterm Results of the Bony Bankart Bridge Technique for the Treatment of  
311 Bony Bankart Lesions. *Am J Sports Med* 47 (1):158-164.
- 312 18. Guo S, Jiang C (2021) "Double-Pulley" Dual-Row Technique for Arthroscopic  
313 Fixation of Large Bony Bankart Lesion: Minimum 2-Year Follow-up With CT  
314 Evaluation. *Orthop J Sports Med* 9 (9):23259671211029239.
- 315 19. Higgins JP, Altman DG, Gotzsche PC, Juni P, Moher D, Oxman AD, Savovic J,  
316 Schulz KF, Weeks L, Sterne JA, Cochrane Bias Methods G, Cochrane Statistical  
317 Methods G (2011) The Cochrane Collaboration's tool for assessing risk of bias in  
318 randomised trials. *BMJ* 343:d5928. doi: 10.1136/bmj.d5928
- 319 20. Horinek JL, Menendez ME, Narbona P, Ladermann A, Barth J, Denard PJ (2022)  
320 Arthroscopic Bankart Repair With Remplissage as an Alternative to Latarjet for  
321 Anterior Glenohumeral Instability With More Than 15% Glenoid Bone Loss. *Orthop  
322 J Sports Med* 10 (12):23259671221142257.
- 323 21. Horner NS, Moroz PA, Bhullar R, Habib A, Simunovic N, Wong I, Bedi A, Ayeni  
324 OR (2018) Open versus arthroscopic Latarjet procedures for the treatment of shoulder  
325 instability: a systematic review of comparative studies. *BMC Musculoskelet Disord*  
326 19 (1):255. doi: 10.1186/s12891-018-2188-2

- 327 22. Hozo SP, Djulbegovic B, Hozo I (2005) Estimating the mean and variance from the  
328 median, range, and the size of a sample. *BMC Med Res Methodol* 5:13. doi:  
329 10.1186/1471-2288-5-13
- 330 23. Hurley ET, Ben Ari E, Lorentz NA, Mojica ES, Colasanti CA, Matache BA, Jazrawi  
331 LM, Virk M, Meislin RJ (2021) Both Open and Arthroscopic Latarjet Result in  
332 Excellent Outcomes and Low Recurrence Rates for Anterior Shoulder Instability.  
333 *Arthrosc Sports Med Rehabil* 3 (6):e1955-e1960. doi: 10.1016/j.asmr.2021.09.017
- 334 24. Hurley ET, Colasanti CA, Lorentz NA, Matache BA, Campbell KA, Jazrawi LM,  
335 Meislin RJ (2022) No Difference in Outcomes After Arthroscopic Bankart Repair  
336 With Remplissage or Arthroscopic Latarjet Procedure for Anterior Shoulder  
337 Instability. *Arthrosc Sports Med Rehabil* 4 (3):e853-e859.
- 338 25. Hurley ET, Jamal MS, Ali ZS, Montgomery C, Pauzenberger L, Mullett H (2019)  
339 Long-term outcomes of the Latarjet procedure for anterior shoulder instability: a  
340 systematic review of studies at 10-year follow-up. *J Shoulder Elbow Surg* 28 (2):e33-  
341 e39.
- 342 26. Hurley ET, Manjunath AK, Matache BA, Jia NW, Virk M, Jazrawi LM, Meislin RJ  
343 (2021) No difference in 90-day complication rate following open versus arthroscopic  
344 Latarjet procedure. *Knee Surg Sports Traumatol Arthrosc* 29 (7):2333-2337.
- 345 27. Hurley ET, Montgomery C, Jamal MS, Shimozone Y, Ali Z, Pauzenberger L, Mullett  
346 H (2019) Return to Play After the Latarjet Procedure for Anterior Shoulder  
347 Instability: A Systematic Review. *Am J Sports Med* 47 (12):3002-3008.
- 348 28. Hurley ET, Toale JP, Davey MS, Colasanti CA, Pauzenberger L, Strauss EJ, Mullett  
349 H (2020) Remplissage for anterior shoulder instability with Hill-Sachs lesions: a  
350 systematic review and meta-analysis. *J Shoulder Elbow Surg* 29 (12):2487-2494.
- 351 29. Kany J, Pankappilly B, Guinand R, Kumar HA, Amaravati RS, Valenti P (2013)  
352 "Bipolar Fixation". *Techniques in Shoulder & Elbow Surgery* 14 (1):10-16.
- 353 30. Kim YK, Cho SH, Son WS, Moon SH (2014) Arthroscopic repair of small and  
354 medium-sized bony Bankart lesions. *Am J Sports Med* 42 (1):86-94.
- 355 31. Kitayama S, Sugaya H, Takahashi N, Matsuki K, Kawai N, Tokai M, Ohnishi K,  
356 Ueda Y, Hoshika S, Kitamura N, Yasuda K, Moriishi J (2015) Clinical Outcome and  
357 Glenoid Morphology After Arthroscopic Repair of Chronic Osseous Bankart Lesions:  
358 A Five to Eight-Year Follow-up Study. *J Bone Joint Surg Am* 97 (22):1833-1843.
- 359 32. Kordasiewicz B, Kicinski M, Malachowski K, Boszczyk A, Chaberek S,  
360 Pomianowski S (2019) Arthroscopic Latarjet Stabilization: Analysis of the Learning  
361 Curve in the First 90 Primary Cases: Early Clinical Results and Computed  
362 Tomography Evaluation. *Arthroscopy* 35 (12):3221-3237.



- 363 33. Lafosse L, Boyle S, Gutierrez-Aramberri M, Shah A, Meller R (2010) Arthroscopic  
364 Latarjet procedure. *Orthop Clin North Am* 41 (3):393-405.
- 365 34. Levy DM, Cole BJ, Bach BR, Jr. (2016) History of surgical intervention of anterior  
366 shoulder instability. *J Shoulder Elbow Surg* 25 (6):e139-150.
- 367 35. Lho T, Lee J, Oh KS, Chung SW (2023) Latarjet procedure for failed Bankart repair  
368 provides better stability and return to sports, but worse postoperative pain and  
369 external rotation limitations with more complications, compared to revision Bankart  
370 repair: a systematic review and meta-analysis. *Knee Surg Sports Traumatol Arthrosc*  
371 31 (8):3541-3558.
- 372 36. Longo UG, Loppini M, Rizzello G, Romeo G, Huijsmans PE, Denaro V (2014)  
373 Glenoid and humeral head bone loss in traumatic anterior glenohumeral instability: a  
374 systematic review. *Knee Surg Sports Traumatol Arthrosc* 22 (2):392-414.
- 375 37. McInnes MDF, Moher D, Thombs BD, McGrath TA, Bossuyt PM, and the P-DTAG,  
376 Clifford T, Cohen JF, Deeks JJ, Gatsonis C, Hooft L, Hunt HA, Hyde CJ, Korevaar  
377 DA, Leeflang MMG, Macaskill P, Reitsma JB, Rodin R, Rutjes AWS, Salameh JP,  
378 Stevens A, Takwoingi Y, Tonelli M, Weeks L, Whiting P, Willis BH (2018) Preferred  
379 Reporting Items for a Systematic Review and Meta-analysis of Diagnostic Test  
380 Accuracy Studies: The PRISMA-DTA Statement. *JAMA* 319 (4):388-396.
- 381 38. Millett PJ, Horan MP, Martetschlager F (2013) The "bony Bankart bridge" technique  
382 for restoration of anterior shoulder stability. *Am J Sports Med* 41 (3):608-614.
- 383 39. Murphy AI, Hurley ET, Hurley DJ, Pauzenberger L, Mullett H (2019) Long-term  
384 outcomes of the arthroscopic Bankart repair: a systematic review of studies at 10-year  
385 follow-up. *J Shoulder Elbow Surg* 28 (11):2084-2089.
- 386 40. Nakagawa S, Hirose T, Uchida R, Ohori T, Mae T (2022) Remaining Large Bone  
387 Fragment of a Bony Bankart Lesion in Shoulders With a Subcritical Glenoid Defect:  
388 Association With Recurrent Anterior Instability. *Am J Sports Med* 50 (1):189-194.
- 389 41. Nakagawa S, Hirose T, Uchida R, Yokoi H, Ohori T, Sahara W, Mae T (2022) A  
390 Glenoid Defect of 13.5% or Larger Is Not Always Critical in Male Competitive  
391 Rugby and American Football Players Undergoing Arthroscopic Bony Bankart  
392 Repair: Contribution of Resultant Large Bone Fragment. *Arthroscopy* 38 (3):673-681.
- 393 42. Nakagawa S, Mae T, Sato S, Okimura S, Kuroda M (2017) Risk Factors for the  
394 Postoperative Recurrence of Instability After Arthroscopic Bankart Repair in  
395 Athletes. *Orthop J Sports Med* 5 (9):2325967117726494.
- 396 43. Nakagawa S, Mae T, Yoneda K, Kinugasa K, Nakamura H (2017) Influence of  
397 Glenoid Defect Size and Bone Fragment Size on the Clinical Outcome After  
398 Arthroscopic Bankart Repair in Male Collision/Contact Athletes. *Am J Sports Med* 45  
399 (9):1967-1974.

- 400 44. Nakagawa S, Ozaki R, Take Y, Mae T, Hayashida K (2015) Bone fragment union and  
401 remodeling after arthroscopic bony bankart repair for traumatic anterior shoulder  
402 instability with a glenoid defect: influence on postoperative recurrence of instability.  
403 Am J Sports Med 43 (6):1438-1447.
- 404 45. Nakagawa S, Uchida R, Yokoi H, Sahara W, Mae T (2019) Changes of Bipolar Bone  
405 Defect Size After Arthroscopic Bankart Repair for Traumatic Anterior Shoulder  
406 Instability: Evaluation Using a Scoring System and Influence on Postoperative  
407 Recurrence. Orthop J Sports Med 7 (11):2325967119885345.
- 408 46. Neyton L, Young A, Dawidziak B, Visona E, Hager JP, Fournier Y, Walch G (2012)  
409 Surgical treatment of anterior instability in rugby union players: clinical and  
410 radiographic results of the Latarjet-Patte procedure with minimum 5-year follow-up. J  
411 Shoulder Elbow Surg 21 (12):1721-1727.
- 412 47. Park I, Lee JH, Hyun HS, Oh MJ, Shin SJ (2018) Effects of Bone Incorporation After  
413 Arthroscopic Stabilization Surgery for Bony Bankart Lesion Based on Preoperative  
414 Glenoid Defect Size. Am J Sports Med 46 (9):2177-2184.
- 415 48. Park JY, Lee SJ, Lhee SH, Lee SH (2012) Follow-up computed tomography  
416 arthrographic evaluation of bony Bankart lesions after arthroscopic repair.  
417 Arthroscopy 28 (4):465-473.
- 418 49. Rai S, Tamang N, Sharma LK, Marasini RP, Singh JL, Khanal K, Ghimire Kc M,  
419 Sherchan B (2021) Comparative study of arthroscopic Bankart repair versus open  
420 Latarjet procedure for recurrent shoulder dislocation. J Int Med Res 49  
421 (4):3000605211007328.
- 422 50. Ranalletta M, Rossi LA, Bertona A, Tanoira I, Hidalgo IA, Maignon GD,  
423 Bongiovanni SL (2018) Modified Latarjet Without Capsulolabral Repair in Rugby  
424 Players With Recurrent Anterior Glenohumeral Instability and Significant Glenoid  
425 Bone Loss. Am J Sports Med 46 (4):795-800.
- 426 51. Rao AJ, Verma NN, Trenhaile SW (2017) The "Floating Labrum": Bankart Lesion  
427 Repair With Anterior Capsular Extension Using 2 Anterior Working Portals. Arthrosc  
428 Tech 6 (5):e1607-e1611. doi: 10.1016/j.eats.2017.06.017
- 429 52. Rattier S, Druel T, Hirakawa Y, Gröger F, van Rooij F, Neyton L (2022) Use of  
430 Cannulated Screws for Primary Latarjet Procedures. Orthop J Sports Med 10  
431 (8):23259671221117802.
- 432 53. Shah N, Nadiri MN, Torrance E, Funk L (2018) Arthroscopic repair of bony Bankart  
433 lesions in collision athletes. Shoulder Elbow 10 (3):201-206.
- 434 54. Shanmugaraj A, Chai D, Sarraj M, Gohal C, Horner NS, Simunovic N, Athwal GS,  
435 Ayeni OR (2021) Surgical stabilization of pediatric anterior shoulder instability yields

- 436 high recurrence rates: a systematic review. *Knee Surg Sports Traumatol Arthrosc* 29  
437 (1):192-201.
- 438 55. Shao Z, Zhao Y, Luo H, Jiang Y, Song Q, Cheng X, Cui G (2022) Clinical and  
439 Radiologic Outcomes of All-Arthroscopic Latarjet Procedure With Modified Suture  
440 Button Fixation: Excellent Bone Healing With a Low Complication Rate.  
441 *Arthroscopy* 38 (7):2157-2165 e2157.
- 442 56. Wang Y, Zhou ZY, Zhang YJ, He CR, Xue CC, Xu WD, Wang ZM (2020) Early  
443 Follow-Up of Arthroscopic Latarjet Procedure with Screw or Suture-Button Fixation  
444 for Recurrent Anterior Shoulder Instability. *Orthop Surg* 12 (5):1350-1361.
- 445 57. Zeng Z, Liu C, Liu Y, Huang Y (2021) Early outcomes of the arthroscopic Latarjet  
446 procedure in a series of 37 patients with shoulder instability. *BMC Musculoskelet*  
447 *Disord* 22 (1):845.
- 448 58. Zhu Y, Jiang C, Song G (2017) Arthroscopic Versus Open Latarjet in the Treatment  
449 of Recurrent Anterior Shoulder Dislocation With Marked Glenoid Bone Loss: A  
450 Prospective Comparative Study. *Am J Sports Med* 45 (7):1645-1653.
- 451 59. Zhu YM, Jiang C, Song G, Lu Y, Li F (2017) Arthroscopic Latarjet Procedure With  
452 Anterior Capsular Reconstruction: Clinical Outcome and Radiologic Evaluation With  
453 a Minimum 2-Year Follow-Up. *Arthroscopy* 33 (12):2128-2135.  
454
- 455

456 **Figure legend**

457 **Figure 1:** Flowchart of study inclusion

458 **Figure 2:** Forest plot on glenoid defect size

459 **Figure 4:** Forest plot on recurrent instability

460 **Figure 5:** Forest plot on union

461 **Figure 6:** Forest plot on postoperative complications

462

463 **Supplementary material:**

464 **Figure 1:** Forest plot on follow-up

465 **Figure 2:** Forest plot on ROWE score

466 **Figure 3:** Forest plot on ASES score

467 **Figure 4:** Forest plot on pain on VAS

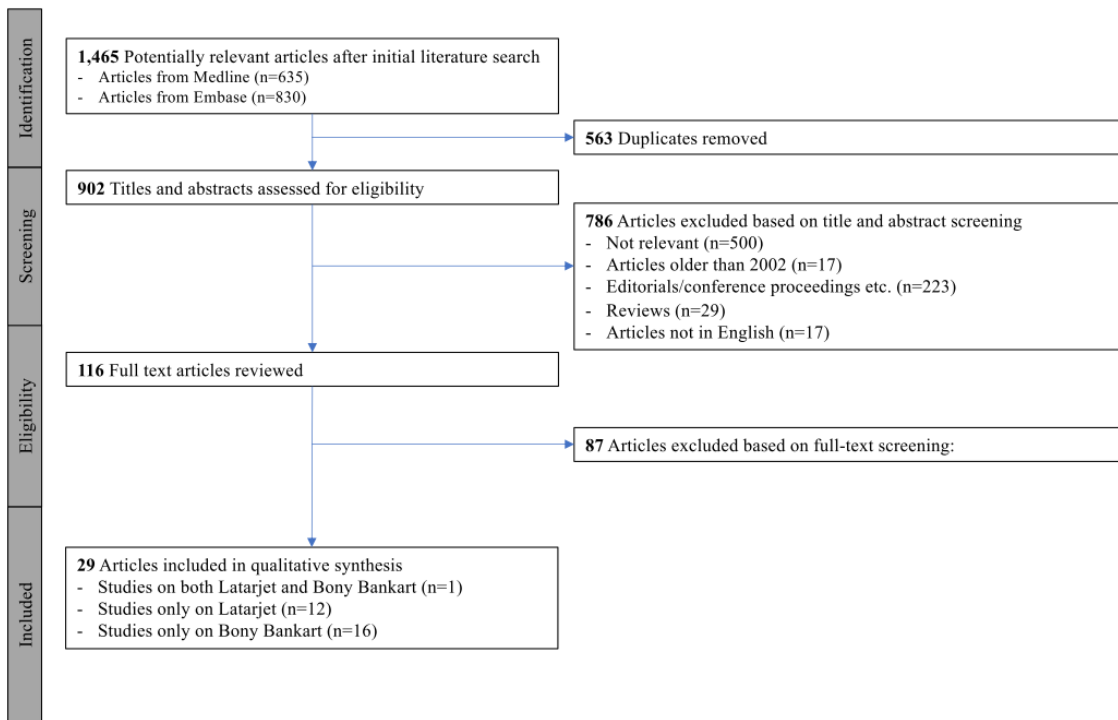
468 **Figure 5:** Forest plot on external rotation 1

469 **Figure 6:** Forest plot on active forward elevation

470 **Appendix 1: Search strategy**

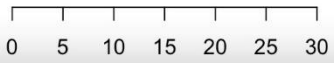
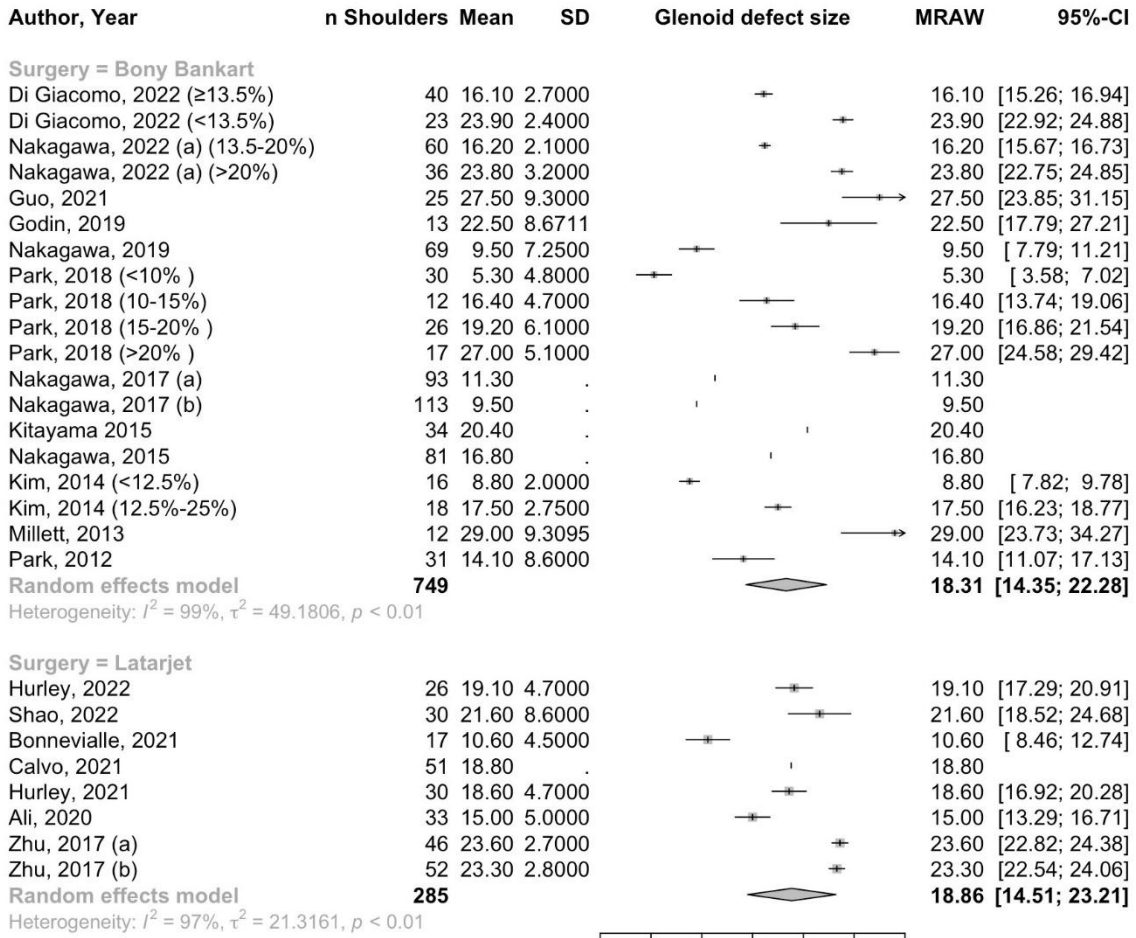
471

472 **F1**



473

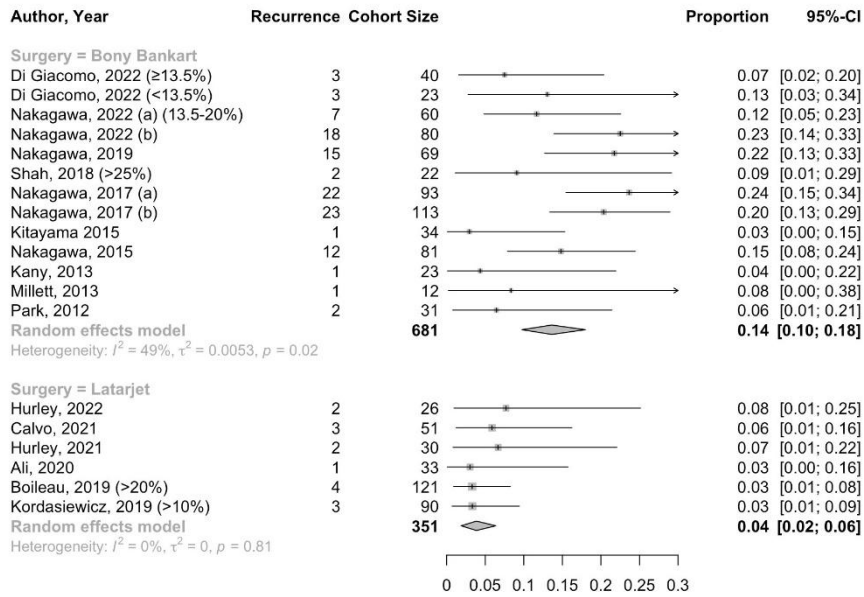
474 **F2**



475

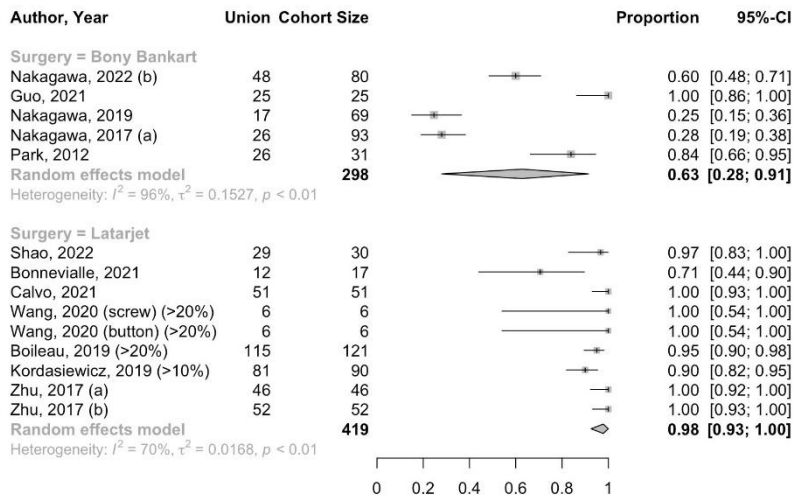
476

477 **F3**



478

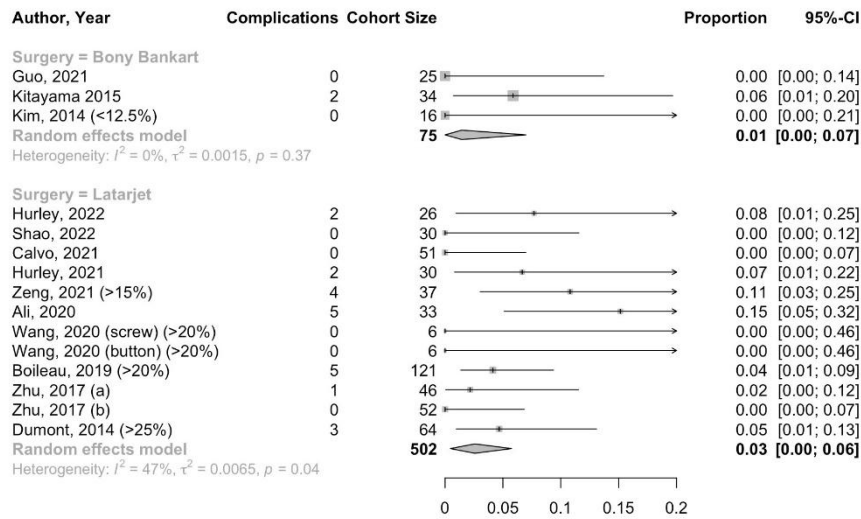
479 **F4**



480

481

482 **F5**



483

484

485 **T1**

**Table 1: Study characteristics of the studies on arthroscopic Latarjet**

Year	Author	Journals	Declare COIs	Have COI	Declare funding	Have funding	Level of evidence	Country
<b>Latarjet</b>								
2022	Hurley	Arthrosc Sports Med Rehabil	Y	Y	Y	Y	III	USA
2022	Shao	Arthroscopy	Y	N	Y	Y	IV	China
2021	Bonnevalle	AJSM	Y	Y	N	NR	III	France
2021	Calvo	AJSM	Y	Y	N	NR	IV	Spain
2021	Hurley	Arthrosc Sports Med Rehabil	Y	Y	N	NR		USA
2021	Zeng	BMC Musculoskeletal Disorders	Y	N	Y	Y		China
2020	Ali	Arthroscopy	Y	N	N	NR	III	Turkey
2020	Wang	Orthop. Surgery	Y	N	Y	N		China
2019	Boileau	Arthroscopy	Y	Y	N	NR	IV	France
2019	Kordasiewicz	KSSTA	Y	N	Y	N		Poland
2017 (a)	Zhu	AJSM	Y	N	Y	Y	IV	China
2017 (b)	Zhu	Arthroscopy	Y	Y	Y	N	III	China
2014	Dumont	AJSM	Y	Y	N	NR	IV	France

486

487 **T2**



**Table 2: Study characteristics of studies on arthroscopic bony Bankart repair**

Year	Author	Journals	Declare COIs	Have COI	Declare funding	Have funding	Level of evidence	Country
<b>Bankart</b>								
2022	Di Giacomo	AJSM	Y	Y	Y	Y	III	Italy and USA
2022 (a)	Nakagawa	AJSM	Y	N	N	NR	IV	Japan
2022 (b)	Nakagawa	Arthroscopy	Y	N	N	NR	III	Japan
2021	Guo	OJSM	N	NR	N	NR	IV	China
2019	Godin	AJSM	Y	Y	Y	Y	IV	USA
2019	Nakagawa	OJSM	Y	N	N	NR	III	Japan
2018	Park	AJSM	Y	Y	Y	Y	III	Korea
2018	Shah	Shoulder and Elbow	Y	N	Y	N		UK
2017 (a)	Nakagawa	AJSM	Y	N	N	NR	III	Japan
2017 (b)	Nakagawa	OJSM	Y	N	N	NR	III	Japan
2015	Kitayama	JBJS-Am	Y	N	Y	N	IV	Japan
2015	Nakagawa	AJSM	Y	N	N	N	III	Japan
2014	Kim	AJSM	Y	Y	N	NR	IV	Korea
2013	Kany	Tech Should Surg	Y	N	N	NR		India/France
2013	Millett	AJSM	Y	Y	Y	Y	IV	USA
2012	Park	Arthroscopy	Y	N	N	NR	IV	South Korea

488

489 **T3**

**Table 3: Patient demographics of studies on arthroscopic Latarjet**

Studies			Patient demographics										
Year	Author	Subgroups	Number of shoulders	Men (%)	Women (%)	Age (mean) ±SD	Mean follow-up (months) ±SD	(Range)	BMI (mean) ±SD	Smoking (%)	Dominant (%)	Hill-Sachs lesions (%)	
<b>Latarjet</b>													
2022	Hurley		26	81%	19%	32 ±13	52	(24 – 90)				100%	
2022	Shao		30	70%	30%	27 ±6	38 ±3				80%	100%	
2021	Bonnevialle		17	82%	18%	22 ±5				23%	47%	59%	
2021	Calvo		51	94%	6%	30 ±8					55%		
2021	Hurley		30	83%	17%	32 ±12	46					100%	
2021	Zeng		37	100%	0%	25 ±5	13	(8 – 22)					
2020	Ali		33	88%	12%	30 ±7	30	(24 – 50)			55%	24%	
2020	Wang	screw	6	100%	0%	23 ±6	25	(10 – 53)	23.4 ±2				
		button	6	100%	0%	23 ±5			24.9 ±5				
2019	Boileau		121	79%	21%	27	26	(24 – 27)		31%	65%		
2019	Kordasiewicz		90	89%	11%	26 ±6	24 ±7	(13 – 50)			61%		
2017(a)	Zhu		46	78%	22%	32 ±10					83%		
2017 (b)	Zhu		52	81%	19%	32 ±10	28	(24 – 42)			69%		
2014	Dumont		64	86%	14%	29	76						

490

Table 4: Patient demographics of studies on arthroscopic bony Bankart repair

Studies			Patient demographics										
Year	Author	Subgroups	Number of shoulders	Men (%)	Women (%)	Age (mean)	±SD	(Range)	Mean follow-up (months)	±SD	(Range)	Dominant (%)	Hill-Sachs lesions (%)
<b>Bankart</b>													
2022	Di Giacomo	≥13.5%	40	100%	0%	26		(19 – 35)	60		(58 – 68)		
		<13.5%	23	100%	0%	26		(19 – 35)	60				
2022 (a)	Nakagawa	Overall	96	89%	11%				29				
		13.5% to ≥20%	60	85%	15%	24 ±10							
2022 (b)	Nakagawa	>20%	36	94%	6%	22 ±7							
		Overall	80						29 ±11		(24 – 67)		16%
		<13.5%	38			18 ±3		(14 – 26)					
		≥13.5%	42			19 ±4		(14 – 29)					
2021	Guo		25	72%	28%	43 ±15			41		(24 – 60)		
2019	Godin		13	100%	0%	40			81		(61 – 108)	39%	100%
2019	Nakagawa		69	100%	0%	18		(14 – 27)			(24)		15%
2018	Park*	Overall	85	91%	9%	26 ±10						71%	
		<10%	30										
		10-15%	12										
		15-20%	26										
		>20%	17										
2018	Shah	(>25%)	22	95%	5%	30		(17 – 66)	28		(24 – 35)	45%	
2017 (a)	Nakagawa		93	100%	0%	17		(14 – 27)					62%
2017 (b)	Nakagawa		113	89%	11%	18							100%
2015	Kitayama		34	91%	9%	24		(15 – 34)	74				
2015	Nakagawa		81	90%	10%	23		(14 – 69)					
2014	Kim	<12.5%	16	100%	0%	25		(17 – 41)	34			75%	
		12.5%-25%	18	89%	11%	32		(19 – 43)	35			61%	
2013	Kany		26	88%	12%	27		(15 – 39)					74%
2013	Millett		15	87%	13%	44		(24 – 70)	32		(24 – 53)	47%	90%
2012	Park		31	94%	6%	23		(15 – 55)	31		(13 – 51)		

\*11 of 223 shoulders has additional remplissage due to engaged Hill-Sachs lesions

