



Virtual surgical planning and three-dimensional printing for the treatment of comminuted zygomaticomaxillary complex fracture

M Longeac, A Depeyre, B Pereira, I Barthelemy, Nathalie Pham Dang

► To cite this version:

M Longeac, A Depeyre, B Pereira, I Barthelemy, Nathalie Pham Dang. Virtual surgical planning and three-dimensional printing for the treatment of comminuted zygomaticomaxillary complex fracture. Journal of Stomatology, Oral and Maxillofacial Surgery, 2021, 122 (4), pp.386. 10.1016/j.jormas.2020.05.009 . hal-03703690

HAL Id: hal-03703690

<https://uca.hal.science/hal-03703690>

Submitted on 16 Oct 2023

HAL is a multi-disciplinary open access archive for the deposit and dissemination of scientific research documents, whether they are published or not. The documents may come from teaching and research institutions in France or abroad, or from public or private research centers.

L'archive ouverte pluridisciplinaire **HAL**, est destinée au dépôt et à la diffusion de documents scientifiques de niveau recherche, publiés ou non, émanant des établissements d'enseignement et de recherche français ou étrangers, des laboratoires publics ou privés.



Distributed under a Creative Commons Attribution - NonCommercial 4.0 International License

VIRTUAL SURGICAL PLANNING AND THREE-DIMENSIONAL PRINTING FOR THE TREATMENT OF COMMINUTED ZYGOMATICOMAXILLARY COMPLEX FRACTURE

Marielle LONGEAC^a, M.D; Practitioner

Arnaud DEPEYRE^a, M.D; Practitioner

Bruno PEREIRA^c, Ph.D., Biostatisticien

Isabelle BARTHELEMY^{a,b}, M.D, Ph.D; Professor, Department Head

Nathalie PHAM DANG^{a,b}, M.D, Ph.D. Practitioner

^a Departement of Oral and Maxillo Facial Surgery, Plastic and Reconstructive Surgery, Estaing Hopital, CHU Clermont Ferrand, Université Clermont Auvergne, 1 place Lucie Aubrac, 63000 Clermont Ferrand, France

^b UMR Inserm/ UdA, Neuro-Dol, Trigeminal Pain and Migraine, BP 10448, 63000 Clermont Ferrand, France

^c Department of Clinical Research and investigation, 58 rue Montalembert, CHU de Clermont-Ferrand, Université Clermont Auvergne Clermont-Ferrand, 63003, France.

Corresponding author: Nathalie PHAM DANG

Departement of Oral and Maxillo Facial Surgery, Plastic and Reconstructive Surgery, Estaing Hopital, CHU Clermont Ferrand, Université Clermont Auvergne, 1 place Lucie Aubrac, 63000 Clermont Ferrand, France

Phone: +33473750102, Fax: +33473750103

E-mail: nphamdang@chu-clermontferrand.fr

Source of support : No

Conflict of Interest: No

Virtual surgical planning and three-dimensional printing for the treatment of comminuted zygomaticomaxillary complex fracture

SUMMARY

Objective: the objective of the study is to evaluate the interest of advanced computer technology, including virtual surgical planning, three-dimensional modeling and pre-bended titanium plate and mesh in the treatment of comminuted zygomaticomaxillary complex fractures.

Material and Methods: A total of 19 patients were included. In the study group (n=6) surgery was combined with preoperative planning including mirroring and bending of the titanium plates and mesh on a 3D model. In the control group (n=13) plates and mesh were bended on the patient during the surgery. Patient characteristics, clinical outcomes, orbital volumes, zygoma projection and complications were recorded.

Results: after surgery, the orbital volume and the zygoma projection variations between injured side and unaffected side were compared. Orbital volume variation was 2.1 mL [1.5; 4.0] in the control group and 0.4 mL [0.1; 1.0] in the study group. Zygoma projection variation was 0.2 cm in the control group and 0.1 cm in the study group. Orbital volume restoration ($p=0.004$) and zygoma symmetrisation ($p=0.04$) were significantly better when titanium plates and meshes were pre-bent on a stereolithographic model.

Conclusion: this study confirms the interest of surgical planification using 3D models to improve treatment of midface trauma.

KEYWORDS: Zygomaticomaxillary complex; Computer-assisted surgery; 3-Dimensional Printing; plates.

INTRODUCTION

Fractures of the zygomaticomaxillary complex (ZMC) are among the most common injuries encountered in craniomaxillofacial trauma [1]. If untreated, they can cause both functional (diplopia, enophthalmos, limitation of mouth opening) and cosmetic (facial asymmetry, loss of zygomatic projection) impairments [2]. Despite major technical improvement in the 20th century, the reduction and osteosynthesis of ZMC fractures are not always easy in comminuted fractures. Management of these fractures has relied mainly on the surgeon's experience. Results for facial contour, symmetry and functional aspect are sometimes disappointing [3–5].

Computer-assisted surgery (CAS) and 3D printing have now become an essential part of the workflow in several fields of oral and maxillofacial surgery, especially in complex reconstructive surgery [6–8]. Using advanced open-source software packages, the surgeon is now able to employ 3D segmentation and mirroring tools, which are highly effective in mimicking the pre-traumatized anatomy at a low cost.

The aim of this study is to compare the results of traditional surgery and of computer technology using a 3D printing model to pre-bend titanium plates in restoration of orbital volume and facial symmetry in the initial management of patients with comminuted ZMC fractures.

PATIENTS AND METHODS

Study Design and Sample

This is an observational retrospective human subjects' study approved by the French University Bioethics Committee; IRB number was 00005921.

Nineteen patients with unilateral comminuted ZMC fractures associated with orbital volume change were included in the study. All were admitted to the Department of Oral and Maxillofacial Surgery, CHU Estaing (Clermont-Ferrand, France) between February 2014 and November 2016.

Patients were divided into two groups: a control group composed of a consecutive cohort of 13 patients treated by conventional surgery, and a study group composed of a consecutive cohort of 6 patients assigned to computer-assisted treatment.

The outcomes, facial symmetry and orbital volume measured on computed tomography before and after surgery were compared between the two groups. Patient follow-up after surgery was 6 months.

Inclusion criteria were:

- comminuted unilateral ZMC fracture with associated orbital fracture, including lateral orbital or orbital floor fractures
- age older than 18 years
- no history of previous or associated craniofacial trauma

Treatment

All patients were operated under general anaesthesia within 15 days following the trauma. Subciliary, intraoral and eyebrow incisions were made to expose the fractures.

Zygomatic reduction was achieved with titanium plates and 5 mm screws (SYNTHES® Matrix Midface 0.8 mm or MEDARTIS MODUS® 2.0). Orbital floor reconstruction was done with titanium orbital meshes (SYNTHES®, Matrix Midface 0.3 mm) or with a PDS plate (ETHICON® ZX5, 0.25 mm). In the study group, titanium meshes and plates were pre-bent according to a 3D stereolithographic model.

Preoperative planning procedure

CT data were imported in DICOM files into the 3D slicer software (Kitware®, N-Y, USA) to create a stereolithographic (STL) file. It was exported in Meshmixer software (Autodesk®, USA). The position of the middle sagittal plane of the skull was established by marking three points (sella, nasion and subspinal) to mirror the uninjured side to the fractured side (Fig. 1). The resulting virtual model was printed (Flashforge® Pro Creator). Titanium plates and mesh were shaped according to the model and sterilized (Fig. 2).

Study variables and outcome parameters

Study variables were epidemiological data and sequelae at 6 months (diplopia, enophthalmos, sensory disorder of the infra-orbital nerve, loss of zygomatic projection and limitation of mouth opening).

Outcome measures comprised: orbital volume and facial symmetry, complications and rate of secondary surgery.

The orbital volumes were measured double-blind in millilitres by a maxillofacial surgeon and a radiologist using OsiriX® MD. Manual segmentation was used to delineate the boundaries of the orbit. A line connecting lateral and medial orbital rim landmarks on each slice defined the anterior limit. The posterior limit was set at the opening of the optic foramen into the orbit. The most superior and inferior axial slices

were confirmed by sagittal plane auto-location on a sagittal-plane view. The computed ROI volume tool was used to automatically calculate volumes of the total selected regions.

ZMC symmetry was measured according to the method of Furst et al.[9]. We selected the axial image slice where the zygomatic arches appeared to be thickest. Three landmarks were then identified:

- axial midline: from the vertical plate of the ethmoid to the midline of the clivus (skull base)
- point A: the most anterolateral point of the zygomatic complex
- point L: the most lateral point of the curve of the zygomatic arch.

We measured the anterior zygomatic complex width (distance between axial midline and point A), the posterior zygomatic complex width (distance between axial midline and point L) and the zygomatic complex projection (distance between points A and L) (Fig.3).

Statistical analysis

Statistical analyses were performed using Stata software version 13 (StataCorp, College Station, TX). The tests were two-sided with the type-I error set at 5%. The continuous data were expressed as the mean \pm standard deviation (SD) or median [interquartile range], according to the statistical distribution. The assumption of normality was assessed with the Shapiro–Wilk’s test. The comparisons between groups were performed using Student t-test or Mann-Whitney test when assumptions required for the t-test were not met. The homoscedasticity was analyzed using Fisher-Snedecor test. The

comparisons concerning categorical data were realized using Chi-squared or Fisher's exact test. For paired comparisons, Student paired t-test or Wilcoxon test were applied.

RESULTS

Patient data

A total of 19 patients were included in the study (15 males and 4 females). Thirteen were treated before February 2016 (conventional surgery group) and 6 after February 2016 with pre-bent plates (study group). Age ranged between 19 and 69 years in the conventional group (mean 36.4 ± 14.8 years) and between 25 and 66 years in the study group (mean 42.7 ± 15.5 years). Patient demographics and cause of injury are given in Table 1.

Patient characteristics in the two groups were similar (gender distribution [$p=0.76$], overall age [$p=0.31$]) as was distribution of the main causes of fractures.

In the control group, Titanium meshes were used for 3/13 (23.1 %) and PDS plates for 10/13 (76.9 %) patients. In the study group, titanium meshes were used for all 6 patients.

Orbital volume restoration (Table. 2)

Preoperative mean orbital volume of the uninjured orbit (OVU_{pro}) was 23.7 ± 2.3 mL in the control group and 23.9 ± 3.1 mL in the study group with no significant difference between the two ($p=0.76$). Mean orbital volume of the uninjured orbit (OVU) was comparable in the two groups ($p=0.82$) and also in the same group before and after surgery ($p=0.16$). Measurement of orbital volume is a repeatable and reproducible method.

Preoperative mean orbital volume of the injured orbit (OVIpro) in the control group was 26.3 ± 2.6 mL with an increase in volume of 2.6 mL compared to the other side. In the study group it was 26.8 ± 2.9 mL with an increase in volume of 2.8 mL. Variation in preoperative orbital volume between the uninjured and injured sides ranged from 2.6 to 2.8 mL ($p=0.51$). The control group and the study group were comparable in terms of trauma.

Postoperative mean orbital volume of the injured orbit (OVIpo) in the control group was 25.8 ± 2.42 mL with a mean decrease of 0.8 mL $[-1.5 ; 1.2]$ and 24.2 ± 3.3 mL in the study group with a decrease in volume of 2.3 ml $[-2.5 ; -2.1]$. Postoperatively, reduction of the orbital volume was statistically higher in the study group ($p=0.03$).

After surgery, comparison of the volume of the restored orbit and that of the contralateral orbit showed a variation of 2.1 mL $[1.5; 4.0]$ in the control group and 0.4 mL $[0.1; 1.0]$ in the study group with a statistical difference between the two ($p=0.004$). Orbital volume restoration was significantly better when titanium meshes were pre-bent on a stereolithographic model.

ZMC symmetry (Table. 3)

Measurements of the contour of the zygoma were made after surgery. Mean zygomatic posterior width of the uninjured-side (UWP) was 6.06 ± 0.25 cm in the control group and 5.99 ± 0.25 cm in the study group. The same measurements were made of the zygoma anterior width with comparable size in the two groups.

Mean zygomatic posterior width of the injured-side (IPW) was 6.35 ± 0.27 cm in the control group and 6.31 ± 0.33 cm in the study group, with no statistical difference between groups. The variation in posterior width between the uninjured and injured

sides was 0.3 cm in each group, with a statistically significant persistent difference ($p=0.001$ to 0.03). Mean zygomatic anterior width of the uninjured side (AWU) was 4.73 ± 0.29 cm in the control group and 4.63 ± 0.15 cm in the study group. It was respectively 4.73 ± 0.35 cm and 4.82 ± 0.23 cm on the injured side (AWI). The difference in anterior width in the control group between injured and uninjured sides was 0.2 [0.1; 0.3] and 0.1 [0.1; 0.3] in the study group, with no statistical difference between the two. Use of pre-bent titanium plates did not increase the quality of the reduction of the anterior and posterior width of the zygoma.

Mean zygomatic projection on the uninjured side (PU) was 3.64 ± 0.45 cm in the control group and 3.69 ± 0.25 cm in the study group. Mean zygomatic projection on the injured side (PI) was 3.76 ± 0.55 cm in the control group and 3.76 ± 0.29 cm in the study group. The difference in projection between injured and uninjured sides was 0.2 cm in the control group and 0.1 cm in the study group, with a statistically significant difference ($p=0.04$). Use of pre-bent titanium plates increased the quality of the projection of the zygoma.

Complications and sequelae

No intraoperative complications were recorded. Because of the small sample size, analyses of each sequela did not provide a reasonable basis for drawing any definite conclusions. However, when all complications and sequelae were analysed as a composite endpoint a significantly lower rate was evidenced in the study group ($p=0.03$) (Supplementary Data, Table 1).

DISCUSSION

In the present study, the authors measured on preoperative and postoperative CT-scan the quality of reduction based on ZMC and orbital cavity marker points. The results indicated a statistically significant improvement in restoring orbital volume ($p=0.004$) and zygoma projection ($p=0.04$) with the use of meshes and pre-bent titanium plates on a 3D printing model. There was also a trend towards fewer complications and sequelae, and without an increase in operating time.

In recent years, there has been extensive literature available on the use of 3D printing methods for the treatment of ZMC fractures. Yet, to be reliable, 3D printed models should be consistent with patient reality. Choi et al. [10] found a mean deviation of 0.56% between the original dry skull and the 3D printed model, which is acceptable for the scheduling of surgical procedures. Moreover, only a few of the published studies used objective benchmarks and many lacked a control group [11,12].

Owing to the complicated anatomy of the ZMC, the great difficulty was in evaluating orbital volume and ZMC shape (13), which requires a standard orientation of the CT-scan slices (14). Values were measured twice, with no inter-observer variation. There was no significant difference between the preoperative and postoperative orbital volumes of the uninjured side ($p=0.16$), which were similar to those obtained in the literature with the same measurement technique [13]. This confirms the reliability and the repeatability of the technique. To analyse ZMC symmetry, we used the method described by Furst et al. (9), which allows the measurement of only anterior and posterior width and projection, it does not take into account each single point of the zygoma. To measure ZMC symmetry exhaustively, other studies have used surface-based matching techniques [2,15] that consist in mirroring of the unaffected side of the

ZMC. Both surfaces are then overlaid, creating an inter-surface distance map representing the amount of symmetry between the two sides. However, the three parameters analysed in the present study - anterior width, posterior width and projection- seem to be more relevant points because they represent the key buttress of the ZMC.

Despite the small number of patients in the study group, the 3D printing method showed its usefulness in restoring orbital volume and in recovering zygomatic projection. Even though in the two groups PDS plates and titanium meshes repartition was not homogenous, we act on the Dietz et al. paper who found no difference in efficacy between titanium meshes and PDS plates [16].

Our study lacks the power to draw significant conclusions concerning other zygoma parameters. In both groups, surgical treatment did not improve posterior and anterior width, probably because of a certain degree of zygoma rotation that was difficult to control during surgery. This means that the 3D printing technique is ineffective in reducing rotation of the zygoma. Combining the technique with a navigation system could overcome this difficulty and further improve surgical precision [17,18].

Analysis of the sequelae and surgical outcomes is limited because based only on binary clinical criteria without any quantitative assessment of the severity of the injury. Moreover, we only considered the bony part of the orbit and did not take into account the periorbital soft tissues, which can play a major role in late enophthalmos development but is a difficult evaluation criterion [8]. Nevertheless, the use of pre-bent 3D plates during orbital surgery allows optimal adaptation and obviates the need for intraoperative plate readjustment thereby reducing oedema, bleeding and nerve lesions.

This would justify a significantly lower rate of complications and sequelae in the study group.

Lastly, as no soft tissues were involved, pre-bending of the titanium mesh on the 3D model was quite easy: mechanical manipulation of the mesh was limited and the mechanical characteristics of the plate were better conserved.

CONCLUSION

Despite a small sample and some bias, this study demonstrated the interest of virtual surgical planning and three-dimensional printing to improve the quality of comminuted zygomaticomaxillary complex fracture reduction with a reasonable cost.

Conflict of interest: No

REFERENCES

1. Ellis E, el-Attar A, Moos KF. An analysis of 2,067 cases of zygomatico-orbital fracture. J Oral Maxillofac Surg Off J Am Assoc Oral Maxillofac Surg. 1985;43(6):417–28.
2. Ho J-PTF, Schreurs R, Milstein DMJ, Dubois L, Maal TJJ, de Lange J, et al. Measuring zygomaticomaxillary complex symmetry three-dimensionally with the use of mirroring and surface based matching techniques. J Cranio-Maxillofac Surg. 2016 Oct;44(10):1706-1712
3. Ellis E, Kittidumkerng W. Analysis of treatment for isolated zygomaticomaxillary complex fractures. J Oral Maxillofac Surg. 1996;54(4):386–400.

4. Zingg M, Laedrach K, Chen J, Chowdhury K, Vuillemin T, Sutter F, et al. Classification and treatment of zygomatic fractures: A review of 1,025 cases. *J Oral Maxillofac Surg.* 1992;50(8):778–90.
5. Makowski GJ, Van Sickels JE. Evaluation of results with three-point visualization of zygomaticomaxillary complex fractures. *Oral Surg Oral Med Oral Pathol Oral Radiol Endod.* 1995;80(6):624–8.
6. Azuma M, Yanagawa T, Ishibashi-Kanno N, Uchida F, Ito T, Yamagata K, et al. Mandibular reconstruction using plates prebent to fit rapid prototyping 3-dimensional printing models ameliorates contour deformity. *Head Face Med* 2014 Oct 23;10:45
7. Liu X-Z, Shu D-L, Ran W, Guo B, Liao X. Digital Surgical Templates for Managing High-Energy Zygomaticomaxillary Complex Injuries Associated With Orbital Volume Change: A Quantitative Assessment. *J Oral Maxillofac Surg.* 2013;71(10):1712–23.
8. Momjian A, Heuberger J, Scolozzi P. [Post-traumatic orbital reconstruction comparing preformed versus non preformed titanium mesh plates]. *Rev Stomatol Chir Maxillofac.* 2011;112(3):145–50.
9. Furst IM, Austin P, Pharoah M, Mahoney J. The use of computed tomography to define zygomatic complex position. *J Oral Maxillofac Surg Off J Am Assoc Oral Maxillofac Surg.* 2001;59(6):647–54.
10. Choi JY, Choi JH, Kim NK, Kim Y, Lee JK, Kim MK, et al. Analysis of errors in medical rapid prototyping models. *Int J Oral Maxillofac Surg.* 2002;31(1):23–32.
11. Cui J, Chen L, Guan X, Ye L, Wang H, Liu L. Surgical planning, three-dimensional model surgery and preshaped implants in treatment of bilateral

- craniomaxillofacial post-traumatic deformities. *J Oral Maxillofac Surg.* 2014;72(6):1138.e1-14.
12. Liu X-Z, Shu D-L, Ran W, Guo B, Liao X. Digital surgical templates for managing high-energy zygomaticomaxillary complex injuries associated with orbital volume change: a quantitative assessment. *J Oral Maxillofac Surg.* 2013;71(10):1712–23.
 13. Shyu VB-H, Hsu C-E, Chen C-H, Chen C-T. 3D-assisted quantitative assessment of orbital volume using an open-source software platform in a Taiwanese population. *PloS One.* 2015;10(3):e0119589.
 14. Deveci M, Öztürk † S, Şengezer ‡ M, Pabuşcu § Y. Measurement of orbital volume by a 3-dimensional software program: An experimental study. *J Oral Maxillofac Surg.* 2000;58(6):645–8.
 15. Klug C, Schicho K, Ploder O, Yerit K, Watzinger F, Ewers R, et al. Point-to-point computer-assisted navigation for precise transfer of planned zygoma osteotomies from the stereolithographic model into reality. *J Oral Maxillofac Surg.* 2006;64(3):550–9.
 16. Dietz A, Ziegler CM, Dacho A, Althof F, Conradt C, Kolling G, et al. Effectiveness of a new perforated 0.15 mm poly-p-dioxanon-foil versus titanium-dynamic mesh in reconstruction of the orbital floor. *J Cranio-Maxillo-fac Surg.* 2001;29(2):82–8.
 17. He D, Li Z, Shi W, Sun Y, Zhu H, Lin M, et al. Orbitozygomatic Fractures With Enophthalmos: Analysis of 64 Cases Treated Late. *J Oral Maxillofac Surg.* 2012;70(3):562–76.

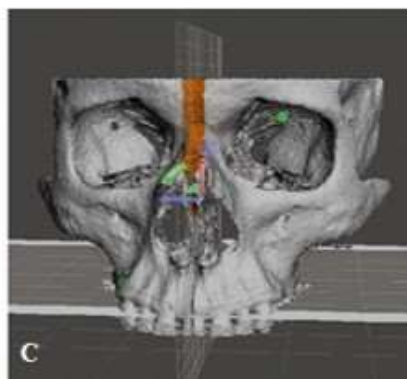
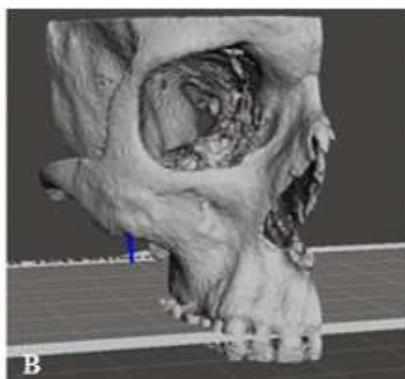
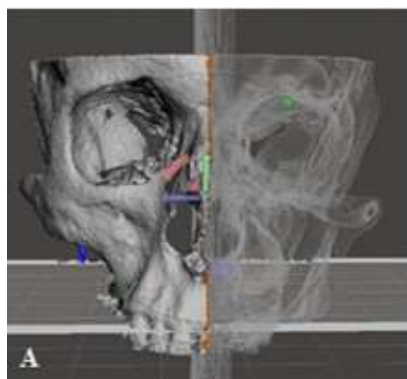
18. Zavattero E, Ramieri G, Roccia F, Gerbino G. Comparison of the Outcomes of Complex Orbital Fracture Repair with and without a Surgical Navigation System: A Prospective Cohort Study with Historical Controls. *Plast Reconstr Surg.* 2017;139(4):957–65.

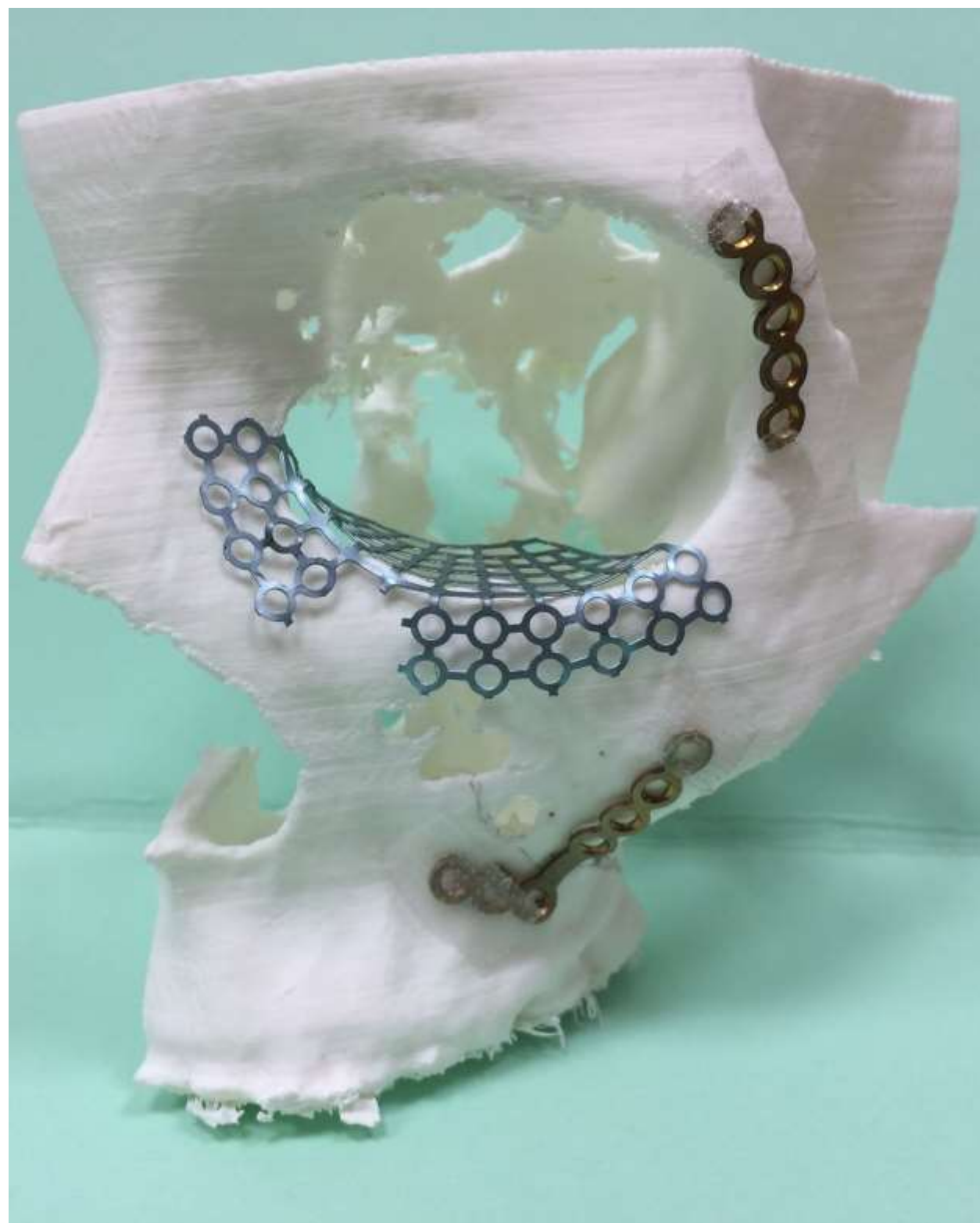CAPTATION OF ILLUSTRATIONS

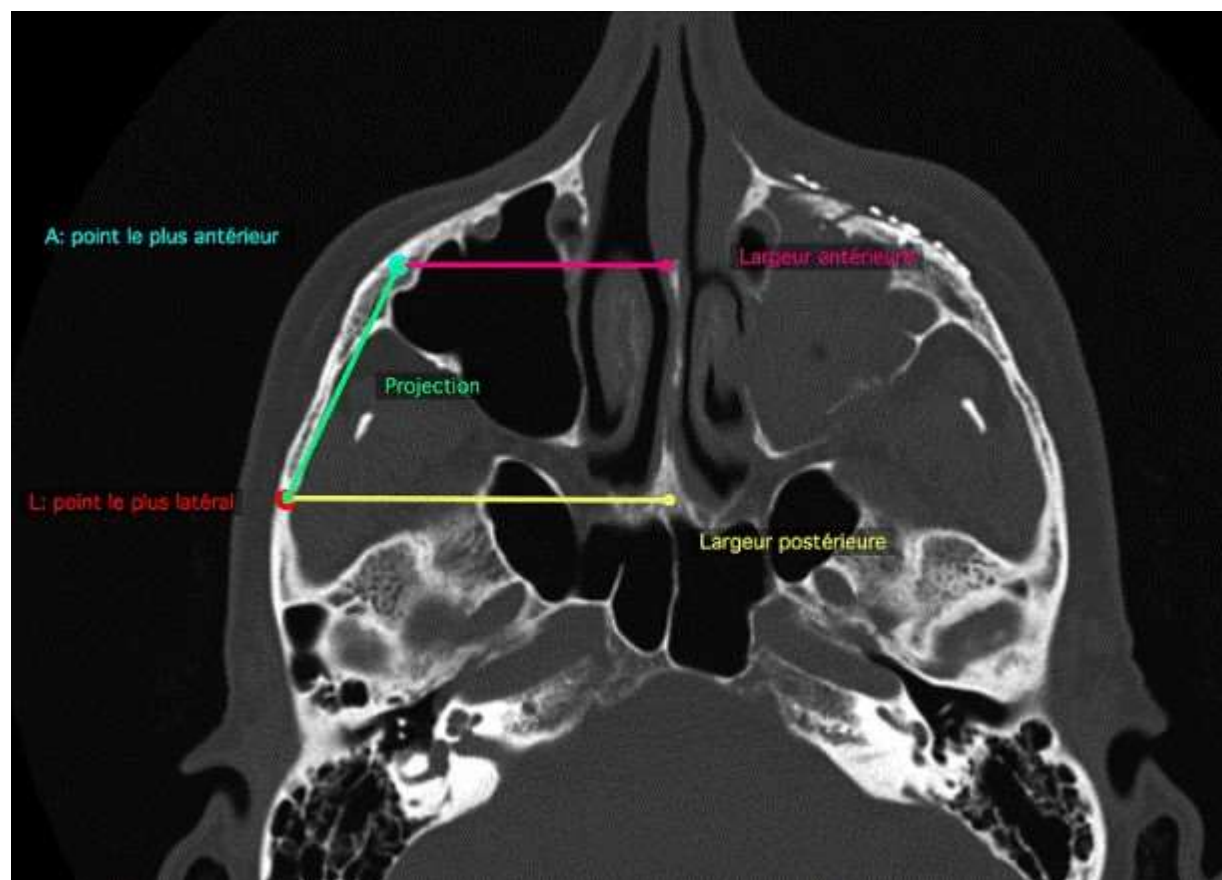
Figure 1: CT data are imported in DICOM files into the 3D slicer software (Kitware®, N-Y, USA) to create a stereolithographic (STL) file. The STL file is exported in Meshmixer software (Autodesk®, USA). A: The position of the middle sagittal plane of the skull established by marking three points (sella, nasion and subspinal), B: after removal of the injured side, C: after mirroring .

Figure 2: The resulted 3D model printed with the Flashforge® Pro Creator, fracture lines and bone defects are drawn on the model. The titanium plates and mesh are shaped according to the patient's specific anatomy.

Figure 3: Landmarks to measure ZMC symmetry. Point A: the most anterolateral point of the zygomatic complex, point L: the most lateral point of the curve of the zygomatic arch, axial midline: from the vertical plate of the ethmoid to the midline of the clivus (skull base) was measured according to the method of Furst et al.(9). We selected the axial image slice where the zygomatic arches appeared to be thickest. Three landmarks were then identified: Using these, we measured the anterior zygomatic complex width (distance between axial midline and point A), the posterior zygomatic complex width (distance between axial midline and point L) and the zygomatic complex projection (distance between points A and L).







	Total	Control	Study Group	P
	n=19	Group n=13	n=6	
Male, n(%)	15 (79.0)	10 (76.9)	5 (83.3)	0.76
Overall age	38.4 ± 14.9	36.4 ± 14.8	42.7 ± 15.5	0.31
Right side, n (%)	6 (31.6)	4 (30.8)	2 (33.3)	0.91
Cause of injury				
Traffic accident, n (%)	3 (15.8)	2 (15.4)	1 (16.7)	1.00
Fall, n (%)	3 (15.8)	2 (15.4)	1 (16.7)	1.00
Interpersonal violence, n (%)	5 (26.3)	3 (23.1)	2 (33.3)	0.65
Sport, n (%)	7 (36.8)	5 (38.5)	2 (33.3)	0.83
Other, n (%)	1 (5.3)	1 (7.7)	0 (0)	1.00
Orbital floor implant				
Titanium mesh, (n%)	9 (47.4)	3 (23.1)	6 (100)	
PDS, (n%)	10 (52.6)	10 (76.9)	0 (0)	

TABLE 1. Patients characteristics, cause of injury and type of implant

Orbital volume (OV) (mL)	Total	Control Group	Study Group	p-value
	n=19	n=13	n=6	
OVUpro	23.8 ± 2.5	23.7 ± 2.3	23.9 ± 3.1	0.76
OVUpo	23.7 ± 2.4	23.6 ± 2.2	23.8 ± 3.1	0.82
<i>p (OVUpro-OVUpo)</i>	<i>0.16</i>	<i>0.25</i>	<i>0.48</i>	
OVIpro	26.5 ± 2.7	26.3 ± 2.6	26.8 ± 2.9	0.86
OVUpro - OVIpro	2.6 [1.7 ; 3.0]	2.6 [1.7 ; 3.0]	2.8 [2.1 ; 3.0]	0.51
OVIpo	25.3 ± 2.7	25.8 ± 2.4	24.2 ± 3.3	0.36
OVIpo - OVIpro	-1.4 [-2.4 ; 0.7]	-0.8 [-1.5 ; 1.2]	-2.3 [-2.5 ; -2.1]	0.03
<i>p (OVIPO-OVIpro)</i>	<i>0.02</i>	<i>0.33</i>	<i>0.003</i>	
OVUpo - OVIpo	1.5 [0.4 ; 3.0]	2.1 [1.5 ; 4.0]	0.4 [0.1 ; 1.0]	0.004

TABLE 2. Mean injured and uninjured orbital volumes (mL) for subjects before and after surgery in the study and control groups and differences between volumes with p values reported. OVUpro: preoperative orbital volume of the uninjured orbit, OVIpro: preoperative orbital volume of the uninjured orbit, OVUpo: postoperative orbital volume of the uninjured orbit, OVIpo: postoperative orbital volume of the injured orbit. OVUpro-OVIpro= volume difference between orbital volume of the uninjured side and orbital volume of the injured side before surgery. OVIpo- OVIpro= volume difference between orbital volume of the injured side after surgery and orbital volume of the injured side before surgery. OVUpo-OVIpo= volume difference between orbital volume of the uninjured side and orbital volume of the injured side after surgery.

Dimension (cm)	Total n=19	Control Group n=13	Study Group n=6	p-value
Posterior width (PW)				
Uninjured side (UPW)	6.04 ± 0.24	6.06 ± 0.25	5.99 ± 0.25	0.42
Injured side (IPW)	6.34 ± 0.28	6.35 ± 0.27	6.31 ± 0.33	0.83
<i>p</i> (UPW,IPW)	<i>0.001</i>	<i>0.001</i>	<i>0.03</i>	
IPW-UPW	0.3[0.2;0.4]	0.3 [0.2; 0.3]	0.3[0.1; 0.5]	1.00
Anterior width (AW)				
Uninjured side (UAW)	4.70 ± 0.25	4.73 ± 0.29	4.63 ± 0.15	0.23
Injured side (IAW)	4.76 ± 0.32	4.73 ± 0.35	4.82 ± 0.23	0.69
<i>p</i> (UAW, IAW)	<i>0.34</i>	<i>1.00</i>	<i>0.006</i>	
IAW-UAW	0.2 [0.1; 0.3]	0.2 [0.1; 0.3]	0.1 [0.1; 0.3]	0.96
Projection (P)				
Uninjured side (UP)	3.66 ± 0.39	3.64 ± 0.45	3.69 ± 0.25	0.96
Injured side (IP)	3.76 ± 0.48	3.76 ± 0.55	3.76 ± 0.29	0.60
<i>p</i> (uninjured-injured)	<i>0.06</i>	<i>0.13</i>	<i>0.10</i>	
IP-UP	0.1 [0.1 ; 0.3]	0.2 [0.1 ; 0.4]	0.1 [0.0 ; 0.1]	0.04

TABLE 3. Mean injured and uninjured ZMC measurements (cm) for subjects before and after surgery in the study and control groups and differences between each side and each group with p values reported. PW= posterior width, AW= anterior width, P= projection, U= Uninjured side , I= Injured side.