



**HAL**  
open science

## Short stems reproduce femoral offset better than standard stems in total hip arthroplasty: a case-control study

Roger Erivan, Anne-Sophie Muller, Guillaume Villatte, Stéphane Millerieux, Aurélien Mulliez, Stéphane Boisgard, Stéphane Descamps

### ► To cite this version:

Roger Erivan, Anne-Sophie Muller, Guillaume Villatte, Stéphane Millerieux, Aurélien Mulliez, et al.. Short stems reproduce femoral offset better than standard stems in total hip arthroplasty: a case-control study. *International Orthopaedics*, 2020, 44 (1), pp.45-51. 10.1007/s00264-019-04355-5 . hal-03118971

**HAL Id: hal-03118971**

**<https://uca.hal.science/hal-03118971v1>**

Submitted on 22 Jan 2021

**HAL** is a multi-disciplinary open access archive for the deposit and dissemination of scientific research documents, whether they are published or not. The documents may come from teaching and research institutions in France or abroad, or from public or private research centers.

L'archive ouverte pluridisciplinaire **HAL**, est destinée au dépôt et à la diffusion de documents scientifiques de niveau recherche, publiés ou non, émanant des établissements d'enseignement et de recherche français ou étrangers, des laboratoires publics ou privés.

# International Orthopaedics

## Short stem reproduces the femoral offset better than conventional stem in total hip arthroplasty, case control study

--Manuscript Draft--

<b>Manuscript Number:</b>	INOR-D-18-02087R2
<b>Full Title:</b>	Short stem reproduces the femoral offset better than conventional stem in total hip arthroplasty, case control study
<b>Article Type:</b>	Original Paper
<b>Funding Information:</b>	
<b>Abstract:</b>	<p>Introduction: In total hip arthroplasty (THA), altering the original offset can lead to poor outcome or even complications or revision when the changes are too great. The aim of the present study was to compare femoral offset between short and standard stems. The hypothesis was that the short stems studied provide better control of postoperative femoral offset.</p> <p>Patients and methods: We retrospectively reviewed 100 consecutive THAs using uncemented optimys™ short stems (Mathys, Bettlach, Switzerland), matched to 100 standard-stem THAs performed during the same period. The primary endpoint was femoral offset; secondary endpoints were limb length and cervico-diaphyseal angle.</p> <p>Results: Mean femoral offset increased by 6.0 +/- 7.2 mm overall (p&lt; 0.0001): 4.7 +/- 6.7 mm in the short-stem group (p&lt;0.0001), and 7.2 +/-7.5 mm in the standard-stem group (p&lt;0.0001), with a significant inter-group difference (p=0.0152). Limb length showed no significant inter-group difference (p=0.8425). Cervico-diaphyseal angle was increased by surgery overall, and more by standard than by short stems (p&lt;0.05).</p> <p>Conclusion: Measurement of femoral offset revealed significant lateralization. It is critical that offset should be maintained in THA. The technique we use increases femoral offset, but the present study showed less increase using short than standard stems. These findings must be borne in mind to achieve good outcome.</p>
<b>Corresponding Author:</b>	Roger Erivan Centre Hospitalier Universitaire de Clermont-Ferrand FRANCE
<b>Corresponding Author Secondary Information:</b>	
<b>Corresponding Author's Institution:</b>	Centre Hospitalier Universitaire de Clermont-Ferrand
<b>Corresponding Author's Secondary Institution:</b>	
<b>First Author:</b>	Roger Erivan
<b>First Author Secondary Information:</b>	
<b>Order of Authors:</b>	Roger Erivan Anne-Sophie MULLER Guillaume VILLATTE Stéphane Millerieux Aurélien MULLIEZ Stéphane BOISGARD Stéphane DESCAMPS
<b>Order of Authors Secondary Information:</b>	
<b>Author Comments:</b>	Please receive this original article which compares optimys short stem's offset to standard stem's. I made all the correction asked. The manuscript is in correction mode, if it is difficult to read like that, I can give it to you without this mode. The entire manuscript has been corrected by an english native translator.

	<p>The order for the authors is the same as the first submission.</p> <p>Best regards</p>
<b>Response to Reviewers:</b>	<p>Hi, I added the comment you suggested about the not perfect xray and I added 2 cases with good x-rays, one with a normal stem, one with a short stem. I changed the number of the other figures.</p> <p>Best regards</p>

# Short ~~stem reproduces the~~ stems reproduce femoral offset better than ~~conventional~~ stem standard stems in total hip arthroplasty; A ~~case-~~ control study

Short title: Femoral offset: short ~~stem~~ versus ~~conventional~~ standard stem

Roger ERIVAN<sup>1\*</sup>, Anne-Sophie MULLER<sup>2</sup>, Guillaume VILLATTE<sup>1</sup>, Stéphane Millerieux<sup>2</sup>, Aurélien MULLIEZ<sup>3</sup>, Stéphane BOISGARD<sup>1</sup>, Stéphane DESCAMPS<sup>1</sup>

1 : Université Clermont Auvergne, CHU Clermont-Ferrand, CNRS, SIGMA Clermont, ICCF, F-63000 Clermont-Ferrand, France

2 : Université Clermont Auvergne, CHU Clermont-Ferrand, F-63000 Clermont-Ferrand, France

3 : Délégation à la Recherche Clinique et aux Innovations (DRCI) - CHU Clermont-Ferrand, F-63000 Clermont-Ferrand, France

\* Corresponding author:

Orthopedic and Trauma Surgery Department, Hôpital Gabriel Montpied, CHU de Clermont Ferrand BP

69, 63003 Clermont Ferrand, France

Phone: +33 4 73 751 535

Email: [rerivan@chu-clermontferrand.fr](mailto:rerivan@chu-clermontferrand.fr)

# Short stems reproduce femoral offset better than standard stems in total hip arthroplasty. A case-control study

**Short title: Femoral offset: short versus standard stem**

**Roger ERIVAN<sup>1\*</sup>, Anne-Sophie MULLER<sup>2</sup>, Guillaume VILLATTE<sup>1</sup>, Stéphane Millerieux<sup>2</sup>, Aurélien MULLIEZ<sup>3</sup>, Stéphane BOISGARD<sup>1</sup>, Stéphane DESCAMPS<sup>1</sup>**

1 : Université Clermont Auvergne, CHU Clermont-Ferrand, CNRS, SIGMA Clermont, ICCF, F-63000 Clermont–Ferrand, France

2 : Université Clermont Auvergne, CHU Clermont-Ferrand, F-63000 Clermont–Ferrand, France

3 : Délégation à la Recherche Clinique et aux Innovations (DRCI) - CHU Clermont-Ferrand, F-63000 Clermont–Ferrand, France

\* Corresponding author:

Orthopedic and Trauma Surgery Department, Hôpital Gabriel Montpied, CHU de Clermont Ferrand BP

69, 63003 Clermont Ferrand, France

Phone: +33 4 73 751 535

Email: [rerivan@chu-clermontferrand.fr](mailto:rerivan@chu-clermontferrand.fr)

# Short stems reproduce femoral offset better than standard stems in total hip arthroplasty. A case-control study

**Short title: Femoral offset: short versus standard stem**

## Abstract

**Introduction:** In total hip arthroplasty (THA), altering the original offset can lead to poor outcome or even complications or revision when the changes are too great. The aim of the present study was to compare femoral offset between short and standard stems. The hypothesis was that the short stems studied provide better control of postoperative femoral offset.

**Patients and methods:** We retrospectively reviewed 100 consecutive THAs using uncemented optimys™ short stems (Mathys, Bettlach, Switzerland), matched to 100 standard-stem THAs performed during the same period. The primary endpoint was femoral offset; secondary endpoints were limb length and cervico-diaphyseal angle.

**Results:** Mean femoral offset increased by 6.0 +/- 7.2 mm overall ( $p < 0.0001$ ): 4.7 +/- 6.7 mm in the short-stem group ( $p < 0.0001$ ), and 7.2 +/- 7.5 mm in the standard-stem group ( $p < 0.0001$ ), with a significant inter-group difference ( $p = 0.0152$ ). Limb length showed no significant inter-group difference ( $p = 0.8425$ ). Cervico-diaphyseal angle was increased by surgery overall, and more by standard than by short stems ( $p < 0.05$ ).

**Conclusion:** Measurement of femoral offset revealed significant lateralization. It is critical that offset should be maintained in THA. The technique we use increases femoral offset, but the present study

showed less increase using short than standard stems. These findings must be borne in mind to achieve good clinical outcome.

Level of evidence: IV, retrospective study

Key-words: femoral offset; short stem; total hip arthroplasty; case-control study

## 1. Introduction

In total hip arthroplasty (THA), it is important to maintain femoral and acetabular offset in order to ensure good joint stability and restore hip abductor muscle function [1–5]. Consequently, preoperative acetabular offset should be maintained [6, 7], and the same is true for the femoral side. Altering the original offset can lead to poor outcome [8] or even complications or revision when the changes are too great [9, 10]. Short stems were developed with the aim of conserving bone stock. Although the first models are very old, long-term survival of the latest-generation stems is not yet known, although clinical results and 8-year survival are excellent [11].

Implant positioning usually spares the femoral neck, with the implant guided along the calcar. This anatomical landmark, with metaphyseal fixation, makes it possible to adapt to particular anatomical situations. Femoral offset with short stems has been rarely studied [12]. Kutzner [13, 14], however, reported femoral offset using the same short stem as in the present study, with an increase in femoral offset of 5.8mm in one study and of 2.2mm in the other; however, he did not compare this to standard stems. Schmidutz compared another model of short stem to a standard stem, but with a modular neck [15].

The aim of the present study was to compare femoral offset between short and standard stems.

The hypothesis was that the short stem studied allows better control of postoperative femoral offset than a standard stem.

## 2. Material and methods

### 2.1 Patients

A case-control study retrospectively reviewed a continuous series of 200 THAs. All were performed with a monoblock cementless (press-fit) cup made of ultra-high molecular weight polyethylene coated with titanium with no metal shell (RM Pressfit™, Mathys, Bettlach, Switzerland). Between 2013 and 2017, we included 100 consecutive THAs using an uncemented optimys™ short stem (Mathys, Bettlach, Switzerland). This short stem is available in standard or lateralized (+5 mm femoral offset) versions. These short stems were matched with 100 standard stems used during the



same period. Two standard stem models were used: cemented CCA™ stem (Mathys, Bettlach, Switzerland) or uncemented twinsys™ (Mathys, Bettlach, Switzerland), according to femoral bone quality. Both were available in standard or lateralized (+5 to +8mm femoral offset, depending on size) versions. Our local review board approved the study (*Comité de Protection des Personnes Sud Est 6*, IRB 8526). Two senior surgeons performed THA.

## 2.2 Methods

Radiographic templates were used for preoperative planning. The femoral neck was cut as planned preoperatively to achieve the desired femoral offset. Either a standard or a lateralized stem was chosen, based on the preoperative plan. The femoral canal was prepared with rasps. A high-viscosity antibiotic-loaded cement (Palacos™ Genta, Hereaus, Hanau, Germany) was injected retrogradely to fix cemented stems.

The surgical approach was anterolateral in most cases, without difference between the two groups. There were 105 left sides, without difference between groups. Cup size was 51.7+/-3.3 mm (range, 44-62), without difference between groups. 89 patients received a ceramic head in the short-stem group, and 67 in the standard group; the other patients received a chrome-cobalt alloy head. Neck lengths in the short-stem group were short (-4mm) in 52 cases, medium in 35 and long (+4mm) in 16. In the standard group, neck lengths were short in 81 cases, medium in 14 and long in 5. The stem used in the short-stem group was lateralized in 80 cases and standard in 20; in the standard group, it was lateralized in 95 cases and standard in 5.

## 2.3 Assessment methods

All patients underwent standardized pre- and post-operative anteroposterior digital X-ray. Orthoview© (Materialise, Belgium) software was used systematically for radiological evaluation of pre- and post-operative offset, and for preoperative planning, as shown in figure 1. In this example, although good pressfit is achieved intra-operatively it is not always reflected by the x-ray. A 30 mm

diameter external marker was used for calibration. All measurements were made by two senior operators (other than the surgical operators).

## 2.4 Statistical methods

Findings were reported as counts and percentages for qualitative and categorical variables and as mean  $\pm$  standard deviation and range for quantitative variables. Groups (short vs standard stem) were compared on chi-square test (or Fisher's exact test, as appropriate) for categorical data and Student t-test for continuous data (or Mann-Whitney test for non-normal distributions). Normal distribution was assessed on distribution plots and Shapiro-Wilk test. Relationships between continuous data were analyzed on Pearson's correlation coefficient (or Spearman's, for non-normal distributions) and scatter plots. Offset, angles and lower-limb length before versus after surgery were compared on paired Student t-test, for the whole sample and by group (short versus standard stem). Concordance between observers' measures (offset, angles and lower-limb length) was assessed on Pearson's (or Spearman's) correlation coefficient, scatter plots and Bland-Altman plots. All analyses used Stata software, version 12 (StataCorp, College Station, TX). All tests were two-sided and a p-value  $<5\%$  was considered statistically significant.

## 3. Results

### 3.1 Follow-up

Mean patient age was 67.1  $\pm$  11.3 years (range, 17-90 years), without difference between groups. 92 patients were female. Mean follow-up was 1.5 years (range, 1–5 years). Pre- and post-operative radiographs were available for all patients. No THA revisions were performed and no patients showed complications or stem movement. Figure 2 and 3 show two examples of patients who had a standard stem and a short stem with measurements of the prosthetic situation before, after surgery and the last follow-up.

### 3.2 Interobserver correlation

Interobserver correlation was good, with correlation coefficient  $r = 0.88$  ( $p < 0.001$ ) for offset,  $r = 0.82$  ( $p < 0.001$ ) for limb length, and  $r = 0.72$  ( $p < 0.001$ ) for neck angle.

### 3.3 Offset results

Mean femoral offset increased by  $6.0 \pm 7.2$  mm overall ( $p < 0.0001$ ):  $4.7 \pm 6.7$  mm in the short-stem group ( $p < 0.0001$ ), and  $7.2 \pm 7.5$  mm in the standard-stem group ( $p < 0.0001$ ), with a significant inter-group difference ( $p = 0.0152$ ). Offset was increased by surgery overall, and more by standard than by short stems. Figure [42](#) shows the distribution of femoral offset variation.

### 3.4 Limb length

Mean limb length increased by  $2.5 \pm 5.5$  mm overall ( $p < 0.0001$ ):  $2.4 \pm 5.0$  mm in the short-stem group ( $p < 0.0001$ ) and  $2.5 \pm 5.9$  mm in the standard-stem group ( $p < 0.0001$ ), without significant inter-group difference ( $p = 0.8425$ ).

### 3.5 Cervico-diaphyseal angle

Mean cervico-diaphyseal angle increased by  $4.5 \pm 6.6^\circ$  overall ( $p < 0.0001$ ):  $2.4 \pm 6.3^\circ$  in the short-stem group ( $p = 0.0002$ ) and  $6.6 \pm 6.4^\circ$  in the standard-stem group ( $p < 0.0001$ ), with significant inter-group difference ( $p < 0.001$ ). Cervico-diaphyseal angle was increased by surgery overall, and more by standard than by short stems. Figure [53](#) shows the changes in cervico-diaphyseal angle.

### 3.6 Inter-group correlation

There were no correlations with gender or neck length except between femoral offset and neck length (Table 1).

Group	criterion		number	mean	standard deviation	minimum	maximum	p
gender F = female M = male	femoral offset	F	92	6.55	7.30	-9.34	26.48	0.30
		H	108	5.48	7.12	-15.57	30.21	
	lower-limb length	F	92	2.10	6.00	-17.40	14.96	0.39
		H	108	2.77	4.95	-16.06	21.06	
	cervico-diaphyseal angle	F	92	4.36	6.81	-16	19	0.76
		H	108	4.66	6.55	-11	16	
neck length S=short M=medium L=long	femoral offset	S	133	6.96	6.63	-5.46	30.21	<b>0.02</b>
		M	46	4.17	8.27	-15.57	23.29	
		L	21	3.64	7.46	-6.53	20.89	
	lower-limb length	S	133	2.44	6.00	-17.40	21.06	0.32
		M	46	1.82	3.95	-7.18	10.77	
		L	21	3.99	4.51	-1.94	13.97	
	cervico-diaphyseal angle	S	133	5.14	6.69	-16	19	0.18
		M	46	3.37	6.92	-11	16	
		L	21	3.12	5.49	-4.5	13.5	

#### 4. Discussion

The study hypothesis was confirmed: short stems provided better control of femoral offset. The mean increase in femoral offset of 6.0 mm was significant and may lead to a loss of strength in abductor muscles [16]. The difference should be smaller with a short stem, in the light of the present results. The aim of short stems is to conserve bone stock and to restore anatomy more effectively [17].

Short stems were introduced as an option for restoring femoral offset and anatomy [13], but restoration of femoral offset compared to standard stems has not previously been studied. Kutzner found the same increase in femoral offset as in the present study, but without control group [13]. The present study shows the importance of preoperative planning. Schmidutz found results similar to those of the present study, but using a short stem with modular neck [15]. Wacha reviewed more than 1,200 short-stem procedures, but did not study femoral offset [18]. A new method for calculating femoral offset was described by Boese in 2016 [19], including rotation of the cervico-

diaphyseal angle measured in the stem to enable femoral offset to be corrected. This method has not been validated for the stem used in the present study, and was therefore not applied here. Some authors recommended use of navigation for restoring offsets and length during surgery; however, this lengthens surgery time [20, 21].

Analysis of the secondary endpoints showed no difference in limb-length between short and standard stem procedures. This parameter can affect clinical results after hip replacement. Amenabar studied limb-length and femoral offset with a different short stem, but did not compare it to a standard stem [12]. The present study compared pre- and post-operative values. One remaining question is whether lower limb length needs to be restored to its value before onset of osteoarthritis or to its value before surgery. Length management is difficult even today [22], and can lead to revision in extreme cases [23]. The present series showed increased length, which is usually what is sought because of length loss induced by osteoarthritis.

Some biases may affect the present study. Offset measurement can be difficult, and some authors recommend CT. The present study did not control stem ante- or retro-version, which can influence offset. The study was retrospective, and a prospective randomized study would be necessary to confirm the present results. Boese showed that the position of the calibration marker is important for calibrating the templating [24]; this is why we corrected the enlargement of the X-ray, to take account of the size of the head in addition to the marker. We used several surgical different approaches, which could induce bias, although Schwarze, in a randomized controlled study, showed no effect of surgical approach on migration of a short-stem total hip prosthesis at 2 years' follow-up [25]. These new generation stems have 96% survival at 4.8 years' follow-up according to Wacha [18], as confirmed by Hauer in a comparative analysis [26]. Short stems can lead to periprosthetic bone remodeling, studied by Yan [27], with onset mainly after 2 years. Short stems are often used with young patients, in order to conserve bone stock. Return to sport after short-stem THA is fast: usually

within 6 months [28]. Short stems are also known to incur less blood loss and fewer transfusions [29]; we did not study these parameters.

## 5. Conclusion

It is critical to maintain offset in THA. The technique we use increases femoral offset, and we need to consider changing it. However, the present study showed that offset was less increased by short than standard stems. These findings must be taken into account so as to optimize clinical outcome.

Conflicts of interest: Stéphane Boigard is an educational consultant for Zimmer-Biomet, outside of this study. The other authors have no conflicts of interest outside of this study. None of the authors have any conflicts of interest to declare relative to this study.

## References

1. Lecerf G, Fessy MH, Philippot R, et al. (2009) Femoral offset: anatomical concept, definition, assessment, implications for preoperative templating and hip arthroplasty. *Orthop Traumatol Surg Res OTSR* 95:210–219. <https://doi.org/10.1016/j.otsr.2009.03.010>
2. McGrory BJ, Morrey BF, Cahalan TD, et al. (1995) Effect of femoral offset on range of motion and abductor muscle strength after total hip arthroplasty. *J Bone Joint Surg Br* 77:865–869
3. Little NJ, Busch CA, Gallagher JA, et al. (2009) Acetabular polyethylene wear and acetabular inclination and femoral offset. *Clin Orthop* 467:2895–2900. <https://doi.org/10.1007/s11999-009-0845-3>
4. Sakalkale DP, Sharkey PF, Eng K, et al. (2001) Effect of femoral component offset on polyethylene wear in total hip arthroplasty. *Clin Orthop* 125–134
5. Chamnongkich S, Asayama I, Kinsey TL, et al. (2012) Difference in hip prosthesis femoral offset affects hip abductor strength and gait characteristics during obstacle crossing. *Orthop Clin North Am* 43:e48-58. <https://doi.org/10.1016/j.ocl.2012.07.008>
6. Takao M, Nishii T, Sakai T, Sugano N (2016) Postoperative Limb-Offset Discrepancy Notably Affects Soft-Tissue Tension in Total Hip Arthroplasty. *J Bone Joint Surg Am* 98:1548–1554. <https://doi.org/10.2106/JBJS.15.01073>
7. Erivan R, Aubret S, Villatte G, et al. (2017) Does using a polyethylene RM press-fit cup modify the preparation of the acetabulum and acetabular offset in primary hip arthroplasty? *Orthop Traumatol Surg Res OTSR*. <https://doi.org/10.1016/j.otsr.2017.03.026>
8. Cassidy KA, Noticewala MS, Macaulay W, et al. (2012) Effect of femoral offset on pain and function after total hip arthroplasty. *J Arthroplasty* 27:1863–1869. <https://doi.org/10.1016/j.arth.2012.05.001>
9. Flecher X, Ollivier M, Argenson JN (2016) Lower limb length and offset in total hip arthroplasty. *Orthop Traumatol Surg Res OTSR* 102:S9-20. <https://doi.org/10.1016/j.otsr.2015.11.001>
10. Wyatt MC, Kieser DC, Kemp MA, et al. (2018) Does the femoral offset affect replacements? The results from a National Joint Registry. *Hip Int J Clin Exp Res Hip Pathol Ther* 1120700018780318. <https://doi.org/10.1177/1120700018780318>
11. Huo S-C, Wang F, Dong L-J, et al. (2016) Short-stem prostheses in primary total hip arthroplasty: A meta-analysis of randomized controlled trials. *Medicine (Baltimore)* 95:e5215. <https://doi.org/10.1097/MD.0000000000005215>
12. Amenabar T, Marimuthu K, Hawdon G, et al. (2015) Total hip arthroplasty using a short-stem prosthesis: restoration of hip anatomy. *J Orthop Surg Hong Kong* 23:90–94. <https://doi.org/10.1177/230949901502300121>
13. Kutzner KP, Kovacevic MP, Roeder C, et al. (2015) Reconstruction of femoro-acetabular offsets using a short-stem. *Int Orthop* 39:1269–1275. <https://doi.org/10.1007/s00264-014-2632-3>
14. Kutzner KP, Pfeil J, Kovacevic MP (2017) Preoperative digital planning versus postoperative outcomes in total hip arthroplasty using a calcar-guided short stem: frequent valgization can be avoided. *Eur J Orthop Surg Traumatol Orthop Traumatol* 27:643–651. <https://doi.org/10.1007/s00590-017-1948-2>

15. Schmidutz F, Beirer M, Weber P, et al. (2012) Biomechanical reconstruction of the hip: comparison between modular short-stem hip arthroplasty and conventional total hip arthroplasty. *Int Orthop* 36:1341–1347. <https://doi.org/10.1007/s00264-011-1477-2>
16. Matsushita A, Nakashima Y, Jingushi S, et al. (2009) Effects of the femoral offset and the head size on the safe range of motion in total hip arthroplasty. *J Arthroplasty* 24:646–651. <https://doi.org/10.1016/j.arth.2008.02.008>
17. Stulberg SD, Patel RM (2013) The short stem: promises and pitfalls. *Bone Jt J* 95-B:57–62. <https://doi.org/10.1302/0301-620X.95B11.32936>
18. Wacha H, Domsel G, Herrmann E (2018) Long-term follow-up of 1217 consecutive short-stem total hip arthroplasty (THA): a retrospective single-center experience. *Eur J Trauma Emerg Surg Off Publ Eur Trauma Soc.* <https://doi.org/10.1007/s00068-017-0895-2>
19. Boese CK, Bredow J, Ettinger M, et al. (2016) The Influence of Hip Rotation on Femoral Offset Following Short Stem Total Hip Arthroplasty. *J Arthroplasty* 31:312–316. <https://doi.org/10.1016/j.arth.2015.07.027>
20. Dastane M, Dorr LD, Tarwala R, Wan Z (2011) Hip offset in total hip arthroplasty: quantitative measurement with navigation. *Clin Orthop* 469:429–436. <https://doi.org/10.1007/s11999-010-1554-7>
21. Paprosky W, Muir J (2016) Intellijoint HIP<sup>®</sup>: a 3D mini-optical navigation tool for improving intraoperative accuracy during total hip arthroplasty. *Med Devices Evid Res Volume* 9:401–408. <https://doi.org/10.2147/MDER.S119161>
22. Loughenbury FA, McWilliams AB, Stewart TD, et al. (2018) Hip surgeons and leg length inequality after primary hip replacement. *Hip Int J Clin Exp Res Hip Pathol Ther* 1120700018777858. <https://doi.org/10.1177/1120700018777858>
23. McWilliams AB, Lampropoulos A, Stone MH (2018) Revision surgery for leg length inequality after primary hip replacement. *Hip Int J Clin Exp Res Hip Pathol Ther* 1120700017752568. <https://doi.org/10.1177/1120700017752568>
24. Boese CK, Bredow J, Dargel J, et al. (2016) Calibration Marker Position in Digital Templating of Total Hip Arthroplasty. *J Arthroplasty* 31:883–887. <https://doi.org/10.1016/j.arth.2015.10.009>
25. Schwarze M, Budde S, von Lewinski G, et al. (2018) No effect of conventional vs. minimally invasive surgical approach on clinical outcome and migration of a short stem total hip prosthesis at 2-year follow-up: A randomized controlled study. *Clin Biomech Bristol Avon* 51:105–112. <https://doi.org/10.1016/j.clinbiomech.2017.12.004>
26. Hauer G, Vielgut I, Amerstorfer F, et al. (2018) Survival Rate of Short-Stem Hip Prostheses: A Comparative Analysis of Clinical Studies and National Arthroplasty Registers. *J Arthroplasty*. <https://doi.org/10.1016/j.arth.2018.01.017>
27. Yan SG, Weber P, Steinbrück A, et al. (2017) Periprosthetic bone remodelling of short-stem total hip arthroplasty: a systematic review. *Int Orthop*. <https://doi.org/10.1007/s00264-017-3691-z>



28. Ortmaier R, Pichler H, Hitzl W, et al. (2017) Return to Sport After Short-Stem Total Hip Arthroplasty. *Clin J Sport Med Off J Can Acad Sport Med*.  
<https://doi.org/10.1097/JSM.0000000000000532>
29. Hochreiter J, Hejkrlik W, Emmanuel K, et al. (2017) Blood loss and transfusion rate in short stem hip arthroplasty. A comparative study. *Int Orthop* 41:1347–1353.  
<https://doi.org/10.1007/s00264-016-3365-2>

## Figure legends

Figure 1: planning with Orthoview® Software

Figure 2: example showing a patient who had a standard stem: A: preoperative X-ray with planification, B: early postoperative (3 months), C: late postoperative with measurement (2 years)

Figure 3: example showing a patient who had a short stem: A: preoperative X-ray with planification, B: early postoperative (1.5 month), C: late postoperative with measurement (4 years)

Figure 42: Distribution of femoral offset variation

Figure 35: Change in cervico-diaphyseal angle

Table 1: Inter-group correlation

# Short stems reproduce femoral offset better than standard stems in total hip arthroplasty. A case-control study

**Short title: Femoral offset: short versus standard stem**

## Abstract

**Introduction:** In total hip arthroplasty (THA), altering the original offset can lead to poor outcome or even complications or revision when the changes are too great. The aim of the present study was to compare femoral offset between short and standard stems. The hypothesis was that the short stems studied provide better control of postoperative femoral offset.

**Patients and methods:** We retrospectively reviewed 100 consecutive THAs using uncemented optimys™ short stems (Mathys, Bettlach, Switzerland), matched to 100 standard-stem THAs performed during the same period. The primary endpoint was femoral offset; secondary endpoints were limb length and cervico-diaphyseal angle.

**Results:** Mean femoral offset increased by 6.0 +/- 7.2 mm overall ( $p < 0.0001$ ): 4.7 +/- 6.7 mm in the short-stem group ( $p < 0.0001$ ), and 7.2 +/- 7.5 mm in the standard-stem group ( $p < 0.0001$ ), with a significant inter-group difference ( $p = 0.0152$ ). Limb length showed no significant inter-group difference ( $p = 0.8425$ ). Cervico-diaphyseal angle was increased by surgery overall, and more by standard than by short stems ( $p < 0.05$ ).

**Conclusion:** Measurement of femoral offset revealed significant lateralization. It is critical that offset should be maintained in THA. The technique we use increases femoral offset, but the present study

showed less increase using short than standard stems. These findings must be borne in mind to achieve good clinical outcome.

Level of evidence: IV, retrospective study

Key-words: femoral offset; short stem; total hip arthroplasty; case-control study

## 1. Introduction

In total hip arthroplasty (THA), it is important to maintain femoral and acetabular offset in order to ensure good joint stability and restore hip abductor muscle function [1–5]. Consequently, preoperative acetabular offset should be maintained [6, 7], and the same is true for the femoral side. Altering the original offset can lead to poor outcome [8] or even complications or revision when the changes are too great [9, 10]. Short stems were developed with the aim of conserving bone stock. Although the first models are very old, long-term survival of the latest-generation stems is not yet known, although clinical results and 8-year survival are excellent [11].

Implant positioning usually spares the femoral neck, with the implant guided along the calcar. This anatomical landmark, with metaphyseal fixation, makes it possible to adapt to particular anatomical situations. Femoral offset with short stems has been rarely studied [12]. Kutzner [13, 14], however, reported femoral offset using the same short stem as in the present study, with an increase in femoral offset of 5.8mm in one study and of 2.2mm in the other; however, he did not compare this to standard stems. Schmidutz compared another model of short stem to a standard stem, but with a modular neck [15].

The aim of the present study was to compare femoral offset between short and standard stems.

The hypothesis was that the short stem studied allows better control of postoperative femoral offset than a standard stem.

## 2. Material and methods

### 2.1 Patients

A case-control study retrospectively reviewed a continuous series of 200 THAs. All were performed with a monoblock cementless (press-fit) cup made of ultra-high molecular weight polyethylene coated with titanium with no metal shell (RM Pressfit™, Mathys, Bettlach, Switzerland). Between 2013 and 2017, we included 100 consecutive THAs using an uncemented optimys™ short stem (Mathys, Bettlach, Switzerland). This short stem is available in standard or lateralized (+5 mm femoral offset) versions. These short stems were matched with 100 standard stems used during the

same period. Two standard stem models were used: cemented CCA™ stem (Mathys, Bettlach, Switzerland) or uncemented twinsys™ (Mathys, Bettlach, Switzerland), according to femoral bone quality. Both were available in standard or lateralized (+5 to +8mm femoral offset, depending on size) versions. Our local review board approved the study (*Comité de Protection des Personnes Sud Est 6*, IRB 8526). Two senior surgeons performed THA.

## 2.2 Methods

Radiographic templates were used for preoperative planning. The femoral neck was cut as planned preoperatively to achieve the desired femoral offset. Either a standard or a lateralized stem was chosen, based on the preoperative plan. The femoral canal was prepared with rasps. A high-viscosity antibiotic-loaded cement (Palacos™ Genta, Hereaus, Hanau, Germany) was injected retrogradely to fix cemented stems.

The surgical approach was anterolateral in most cases, without difference between the two groups. There were 105 left sides, without difference between groups. Cup size was 51.7+/-3.3 mm (range, 44-62), without difference between groups. 89 patients received a ceramic head in the short-stem group, and 67 in the standard group; the other patients received a chrome-cobalt alloy head. Neck lengths in the short-stem group were short (-4mm) in 52 cases, medium in 35 and long (+4mm) in 16. In the standard group, neck lengths were short in 81 cases, medium in 14 and long in 5. The stem used in the short-stem group was lateralized in 80 cases and standard in 20; in the standard group, it was lateralized in 95 cases and standard in 5.

## 2.3 Assessment methods

All patients underwent standardized pre- and post-operative anteroposterior digital X-ray. Orthoview© (Materialise, Belgium) software was used systematically for radiological evaluation of pre- and post-operative offset, and for preoperative planning, as shown in figure 1. In this example, although good pressfit is achieved intra-operatively it is not always reflected by the x-ray. A 30 mm

diameter external marker was used for calibration. All measurements were made by two senior operators (other than the surgical operators).

## 2.4 Statistical methods

Findings were reported as counts and percentages for qualitative and categorical variables and as mean  $\pm$  standard deviation and range for quantitative variables. Groups (short vs standard stem) were compared on chi-square test (or Fisher's exact test, as appropriate) for categorical data and Student t-test for continuous data (or Mann-Whitney test for non-normal distributions). Normal distribution was assessed on distribution plots and Shapiro-Wilk test. Relationships between continuous data were analyzed on Pearson's correlation coefficient (or Spearman's, for non-normal distributions) and scatter plots. Offset, angles and lower-limb length before versus after surgery were compared on paired Student t-test, for the whole sample and by group (short versus standard stem). Concordance between observers' measures (offset, angles and lower-limb length) was assessed on Pearson's (or Spearman's) correlation coefficient, scatter plots and Bland-Altman plots. All analyses used Stata software, version 12 (StataCorp, College Station, TX). All tests were two-sided and a p-value  $<5\%$  was considered statistically significant.

## 3. Results

### 3.1 Follow-up

Mean patient age was 67.1  $\pm$  11.3 years (range, 17-90 years), without difference between groups. 92 patients were female. Mean follow-up was 1.5 years (range, 1–5 years). Pre- and post-operative radiographs were available for all patients. No THA revisions were performed and no patients showed complications or stem movement. Figure 2 and 3 show two examples of patients who had a standard stem and a short stem with measurements of the prosthetic situation before, after surgery and the last follow-up.

### 3.2 Interobserver correlation

Interobserver correlation was good, with correlation coefficient  $r = 0.88$  ( $p < 0.001$ ) for offset,  $r = 0.82$  ( $p < 0.001$ ) for limb length, and  $r = 0.72$  ( $p < 0.001$ ) for neck angle.

### 3.3 Offset results

Mean femoral offset increased by  $6.0 \pm 7.2$  mm overall ( $p < 0.0001$ ):  $4.7 \pm 6.7$  mm in the short-stem group ( $p < 0.0001$ ), and  $7.2 \pm 7.5$  mm in the standard-stem group ( $p < 0.0001$ ), with a significant inter-group difference ( $p = 0.0152$ ). Offset was increased by surgery overall, and more by standard than by short stems. Figure 4 shows the distribution of femoral offset variation.

### 3.4 Limb length

Mean limb length increased by  $2.5 \pm 5.5$  mm overall ( $p < 0.0001$ ):  $2.4 \pm 5.0$  mm in the short-stem group ( $p < 0.0001$ ) and  $2.5 \pm 5.9$  mm in the standard-stem group ( $p < 0.0001$ ), without significant inter-group difference ( $p = 0.8425$ ).

### 3.5 Cervico-diaphyseal angle

Mean cervico-diaphyseal angle increased by  $4.5 \pm 6.6^\circ$  overall ( $p < 0.0001$ ):  $2.4 \pm 6.3^\circ$  in the short-stem group ( $p = 0.0002$ ) and  $6.6 \pm 6.4^\circ$  in the standard-stem group ( $p < 0.0001$ ), with significant inter-group difference ( $p < 0.001$ ). Cervico-diaphyseal angle was increased by surgery overall, and more by standard than by short stems. Figure 5 shows the changes in cervico-diaphyseal angle.

### 3.6 Inter-group correlation

There were no correlations with gender or neck length except between femoral offset and neck length (Table 1).



Group	criterion		number	mean	standard deviation	minimum	maximum	p
gender F = female M = male	femoral offset	F	92	6.55	7.30	-9.34	26.48	0.30
		H	108	5.48	7.12	-15.57	30.21	
	lower-limb length	F	92	2.10	6.00	-17.40	14.96	0.39
		H	108	2.77	4.95	-16.06	21.06	
	cervico-diaphyseal angle	F	92	4.36	6.81	-16	19	0.76
		H	108	4.66	6.55	-11	16	
neck length S=short M=medium L=long	femoral offset	S	133	6.96	6.63	-5.46	30.21	<b>0.02</b>
		M	46	4.17	8.27	-15.57	23.29	
		L	21	3.64	7.46	-6.53	20.89	
	lower-limb length	S	133	2.44	6.00	-17.40	21.06	0.32
		M	46	1.82	3.95	-7.18	10.77	
		L	21	3.99	4.51	-1.94	13.97	
	cervico-diaphyseal angle	S	133	5.14	6.69	-16	19	0.18
		M	46	3.37	6.92	-11	16	
		L	21	3.12	5.49	-4.5	13.5	

#### 4. Discussion

The study hypothesis was confirmed: short stems provided better control of femoral offset. The mean increase in femoral offset of 6.0 mm was significant and may lead to a loss of strength in abductor muscles [16]. The difference should be smaller with a short stem, in the light of the present results. The aim of short stems is to conserve bone stock and to restore anatomy more effectively [17].

Short stems were introduced as an option for restoring femoral offset and anatomy [13], but restoration of femoral offset compared to standard stems has not previously been studied. Kutzner found the same increase in femoral offset as in the present study, but without control group [13]. The present study shows the importance of preoperative planning. Schmidutz found results similar to those of the present study, but using a short stem with modular neck [15]. Wacha reviewed more than 1,200 short-stem procedures, but did not study femoral offset [18]. A new method for calculating femoral offset was described by Boese in 2016 [19], including rotation of the cervico-

diaphyseal angle measured in the stem to enable femoral offset to be corrected. This method has not been validated for the stem used in the present study, and was therefore not applied here. Some authors recommended use of navigation for restoring offsets and length during surgery; however, this lengthens surgery time [20, 21].

Analysis of the secondary endpoints showed no difference in limb-length between short and standard stem procedures. This parameter can affect clinical results after hip replacement. Amenabar studied limb-length and femoral offset with a different short stem, but did not compare it to a standard stem [12]. The present study compared pre- and post-operative values. One remaining question is whether lower limb length needs to be restored to its value before onset of osteoarthritis or to its value before surgery. Length management is difficult even today [22], and can lead to revision in extreme cases [23]. The present series showed increased length, which is usually what is sought because of length loss induced by osteoarthritis.

Some biases may affect the present study. Offset measurement can be difficult, and some authors recommend CT. The present study did not control stem ante- or retro-version, which can influence offset. The study was retrospective, and a prospective randomized study would be necessary to confirm the present results. Boese showed that the position of the calibration marker is important for calibrating the templating [24]; this is why we corrected the enlargement of the X-ray, to take account of the size of the head in addition to the marker. We used several surgical different approaches, which could induce bias, although Schwarze, in a randomized controlled study, showed no effect of surgical approach on migration of a short-stem total hip prosthesis at 2 years' follow-up [25]. These new generation stems have 96% survival at 4.8 years' follow-up according to Wacha [18], as confirmed by Hauer in a comparative analysis [26]. Short stems can lead to periprosthetic bone remodeling, studied by Yan [27], with onset mainly after 2 years. Short stems are often used with young patients, in order to conserve bone stock. Return to sport after short-stem THA is fast: usually

within 6 months [28]. Short stems are also known to incur less blood loss and fewer transfusions [29]; we did not study these parameters.

## 5. Conclusion

It is critical to maintain offset in THA. The technique we use increases femoral offset, and we need to consider changing it. However, the present study showed that offset was less increased by short than standard stems. These findings must be taken into account so as to optimize clinical outcome.

Conflicts of interest: Stéphane Boigard is an educational consultant for Zimmer-Biomet, outside of this study. The other authors have no conflicts of interest outside of this study. None of the authors have any conflicts of interest to declare relative to this study.

## References

1. Lecerf G, Fessy MH, Philippot R, et al. (2009) Femoral offset: anatomical concept, definition, assessment, implications for preoperative templating and hip arthroplasty. *Orthop Traumatol Surg Res OTSR* 95:210–219. <https://doi.org/10.1016/j.otsr.2009.03.010>
2. McGrory BJ, Morrey BF, Cahalan TD, et al. (1995) Effect of femoral offset on range of motion and abductor muscle strength after total hip arthroplasty. *J Bone Joint Surg Br* 77:865–869
3. Little NJ, Busch CA, Gallagher JA, et al. (2009) Acetabular polyethylene wear and acetabular inclination and femoral offset. *Clin Orthop* 467:2895–2900. <https://doi.org/10.1007/s11999-009-0845-3>
4. Sakalkale DP, Sharkey PF, Eng K, et al. (2001) Effect of femoral component offset on polyethylene wear in total hip arthroplasty. *Clin Orthop* 125–134
5. Chamnongkich S, Asayama I, Kinsey TL, et al. (2012) Difference in hip prosthesis femoral offset affects hip abductor strength and gait characteristics during obstacle crossing. *Orthop Clin North Am* 43:e48-58. <https://doi.org/10.1016/j.ocl.2012.07.008>
6. Takao M, Nishii T, Sakai T, Sugano N (2016) Postoperative Limb-Offset Discrepancy Notably Affects Soft-Tissue Tension in Total Hip Arthroplasty. *J Bone Joint Surg Am* 98:1548–1554. <https://doi.org/10.2106/JBJS.15.01073>
7. Erivan R, Aubret S, Villatte G, et al. (2017) Does using a polyethylene RM press-fit cup modify the preparation of the acetabulum and acetabular offset in primary hip arthroplasty? *Orthop Traumatol Surg Res OTSR*. <https://doi.org/10.1016/j.otsr.2017.03.026>
8. Cassidy KA, Noticewala MS, Macaulay W, et al. (2012) Effect of femoral offset on pain and function after total hip arthroplasty. *J Arthroplasty* 27:1863–1869. <https://doi.org/10.1016/j.arth.2012.05.001>
9. Flecher X, Ollivier M, Argenson JN (2016) Lower limb length and offset in total hip arthroplasty. *Orthop Traumatol Surg Res OTSR* 102:S9-20. <https://doi.org/10.1016/j.otsr.2015.11.001>
10. Wyatt MC, Kieser DC, Kemp MA, et al. (2018) Does the femoral offset affect replacements? The results from a National Joint Registry. *Hip Int J Clin Exp Res Hip Pathol Ther* 1120700018780318. <https://doi.org/10.1177/1120700018780318>
11. Huo S-C, Wang F, Dong L-J, et al. (2016) Short-stem prostheses in primary total hip arthroplasty: A meta-analysis of randomized controlled trials. *Medicine (Baltimore)* 95:e5215. <https://doi.org/10.1097/MD.0000000000005215>
12. Amenabar T, Marimuthu K, Hawdon G, et al. (2015) Total hip arthroplasty using a short-stem prosthesis: restoration of hip anatomy. *J Orthop Surg Hong Kong* 23:90–94. <https://doi.org/10.1177/230949901502300121>
13. Kutzner KP, Kovacevic MP, Roeder C, et al. (2015) Reconstruction of femoro-acetabular offsets using a short-stem. *Int Orthop* 39:1269–1275. <https://doi.org/10.1007/s00264-014-2632-3>
14. Kutzner KP, Pfeil J, Kovacevic MP (2017) Preoperative digital planning versus postoperative outcomes in total hip arthroplasty using a calcar-guided short stem: frequent valgization can be avoided. *Eur J Orthop Surg Traumatol Orthop Traumatol* 27:643–651. <https://doi.org/10.1007/s00590-017-1948-2>

15. Schmidutz F, Beirer M, Weber P, et al. (2012) Biomechanical reconstruction of the hip: comparison between modular short-stem hip arthroplasty and conventional total hip arthroplasty. *Int Orthop* 36:1341–1347. <https://doi.org/10.1007/s00264-011-1477-2>
16. Matsushita A, Nakashima Y, Jingushi S, et al. (2009) Effects of the femoral offset and the head size on the safe range of motion in total hip arthroplasty. *J Arthroplasty* 24:646–651. <https://doi.org/10.1016/j.arth.2008.02.008>
17. Stulberg SD, Patel RM (2013) The short stem: promises and pitfalls. *Bone Jt J* 95-B:57–62. <https://doi.org/10.1302/0301-620X.95B11.32936>
18. Wacha H, Domsel G, Herrmann E (2018) Long-term follow-up of 1217 consecutive short-stem total hip arthroplasty (THA): a retrospective single-center experience. *Eur J Trauma Emerg Surg Off Publ Eur Trauma Soc.* <https://doi.org/10.1007/s00068-017-0895-2>
19. Boese CK, Bredow J, Ettinger M, et al. (2016) The Influence of Hip Rotation on Femoral Offset Following Short Stem Total Hip Arthroplasty. *J Arthroplasty* 31:312–316. <https://doi.org/10.1016/j.arth.2015.07.027>
20. Dastane M, Dorr LD, Tarwala R, Wan Z (2011) Hip offset in total hip arthroplasty: quantitative measurement with navigation. *Clin Orthop* 469:429–436. <https://doi.org/10.1007/s11999-010-1554-7>
21. Paprosky W, Muir J (2016) Intellijoint HIP<sup>®</sup>: a 3D mini-optical navigation tool for improving intraoperative accuracy during total hip arthroplasty. *Med Devices Evid Res Volume* 9:401–408. <https://doi.org/10.2147/MDER.S119161>
22. Loughenbury FA, McWilliams AB, Stewart TD, et al. (2018) Hip surgeons and leg length inequality after primary hip replacement. *Hip Int J Clin Exp Res Hip Pathol Ther* 1120700018777858. <https://doi.org/10.1177/1120700018777858>
23. McWilliams AB, Lampropoulos A, Stone MH (2018) Revision surgery for leg length inequality after primary hip replacement. *Hip Int J Clin Exp Res Hip Pathol Ther* 1120700017752568. <https://doi.org/10.1177/1120700017752568>
24. Boese CK, Bredow J, Dargel J, et al. (2016) Calibration Marker Position in Digital Templating of Total Hip Arthroplasty. *J Arthroplasty* 31:883–887. <https://doi.org/10.1016/j.arth.2015.10.009>
25. Schwarze M, Budde S, von Lewinski G, et al. (2018) No effect of conventional vs. minimally invasive surgical approach on clinical outcome and migration of a short stem total hip prosthesis at 2-year follow-up: A randomized controlled study. *Clin Biomech Bristol Avon* 51:105–112. <https://doi.org/10.1016/j.clinbiomech.2017.12.004>
26. Hauer G, Vielgut I, Amerstorfer F, et al. (2018) Survival Rate of Short-Stem Hip Prostheses: A Comparative Analysis of Clinical Studies and National Arthroplasty Registers. *J Arthroplasty*. <https://doi.org/10.1016/j.arth.2018.01.017>
27. Yan SG, Weber P, Steinbrück A, et al. (2017) Periprosthetic bone remodelling of short-stem total hip arthroplasty: a systematic review. *Int Orthop*. <https://doi.org/10.1007/s00264-017-3691-z>

28. Ortmaier R, Pichler H, Hitzl W, et al. (2017) Return to Sport After Short-Stem Total Hip Arthroplasty. *Clin J Sport Med Off J Can Acad Sport Med*.  
<https://doi.org/10.1097/JSM.0000000000000532>
29. Hochreiter J, Hejkrlik W, Emmanuel K, et al. (2017) Blood loss and transfusion rate in short stem hip arthroplasty. A comparative study. *Int Orthop* 41:1347–1353.  
<https://doi.org/10.1007/s00264-016-3365-2>

## Figure legends

Figure 1: planning with Orthoview® Software

Figure 2: example showing a patient who had a standard stem: A: preoperative X-ray with planification, B: early postoperative (3 months), C: late postoperative with measurement (2 years)

Figure 3: example showing a patient who had a short stem: A: preoperative X-ray with planification, B: early postoperative (1.5 month), C: late postoperative with measurement (4 years)

Figure 4: Distribution of femoral offset variation

Figure 5: Change in cervico-diaphyseal angle

Table 1: Inter-group correlation

Sub- groupeGroup	criterion		number	mean	standard deviation	minimum	maximum	p
<del>sexe</del> <del>W=woman</del> <del>M=man</del> gender <del>F = female</del> <del>M = male</del>	femoral offset	F	92	6.55	7.30	-9.34	26.48	0.30
		M	108	5.48	7.12	-15.57	30.21	
	lower-limb length	F	92	2.10	6.00	-17.40	14.96	0.39
		M	108	2.77	4.95	-16.06	21.06	
	cervico-diaphyseal angle	F	92	4.36	6.81	-16	19	0.76
		M	108	4.66	6.55	-11	16	
neck length S=short M=medium L=long	femoral offset	S	133	6.96	6.63	-5.46	30.21	<b>0.02</b>
		M	46	4.17	8.27	-15.57	23.29	
		L	21	3.64	7.46	-6.53	20.89	
	lower-limb length	S	133	2.44	6.00	-17.40	21.06	0.32
		M	46	1.82	3.95	-7.18	10.77	
		L	21	3.99	4.51	-1.94	13.97	
	cervico-diaphyseal angle	S	133	5.14	6.69	-16	19	0.18
		M	46	3.37	6.92	-11	16	
		L	21	3.12	5.49	-4.5	13.5	



Group	criterion		number	mean	standard deviation	minimum	maximum	p
gender F = female M = male	femoral offset	F	92	6.55	7.30	-9.34	26.48	0.30
		M	108	5.48	7.12	-15.57	30.21	
	lower-limb length	F	92	2.10	6.00	-17.40	14.96	0.39
		M	108	2.77	4.95	-16.06	21.06	
	cervico-diaphyseal angle	F	92	4.36	6.81	-16	19	0.76
		M	108	4.66	6.55	-11	16	
neck length S=short M=medium L=long	femoral offset	S	133	6.96	6.63	-5.46	30.21	<b>0.02</b>
		M	46	4.17	8.27	-15.57	23.29	
		L	21	3.64	7.46	-6.53	20.89	
	lower-limb length	S	133	2.44	6.00	-17.40	21.06	0.32
		M	46	1.82	3.95	-7.18	10.77	
		L	21	3.99	4.51	-1.94	13.97	
	cervico-diaphyseal angle	S	133	5.14	6.69	-16	19	0.18
		M	46	3.37	6.92	-11	16	
		L	21	3.12	5.49	-4.5	13.5	

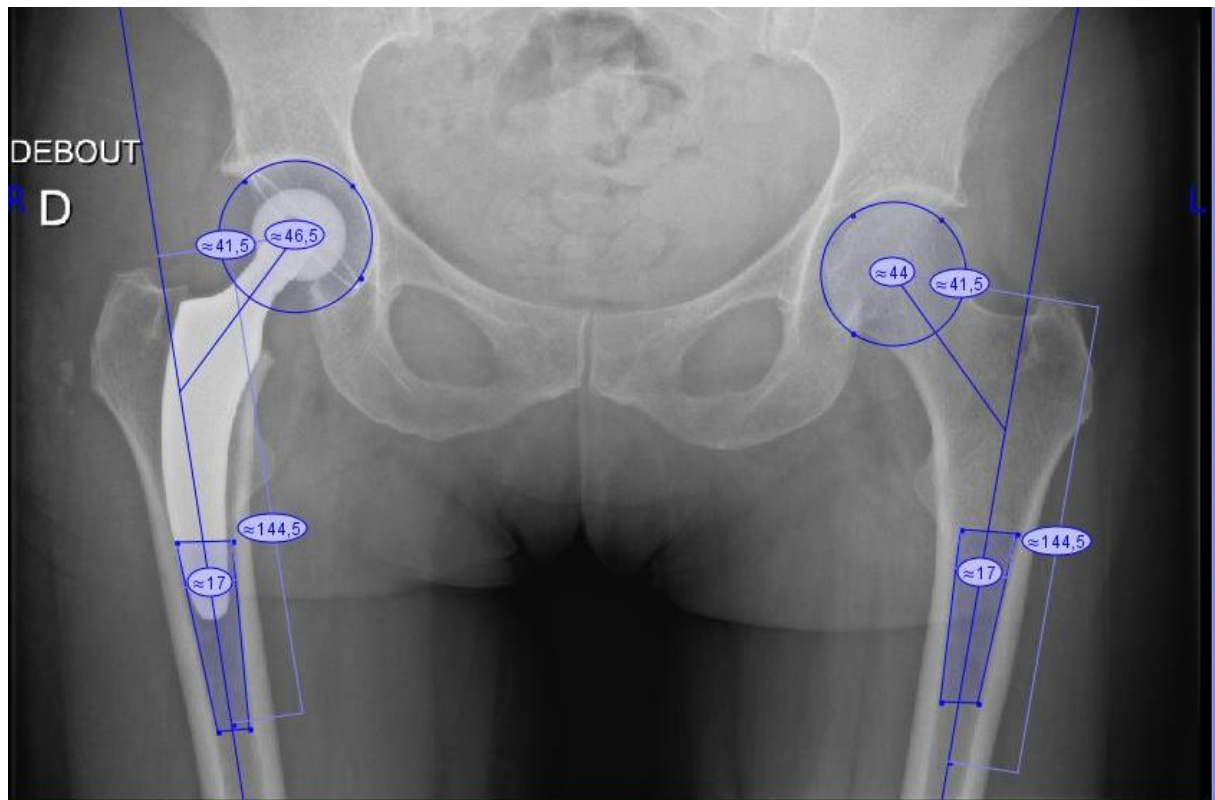


Figure 1: planning with Orthoview®Software

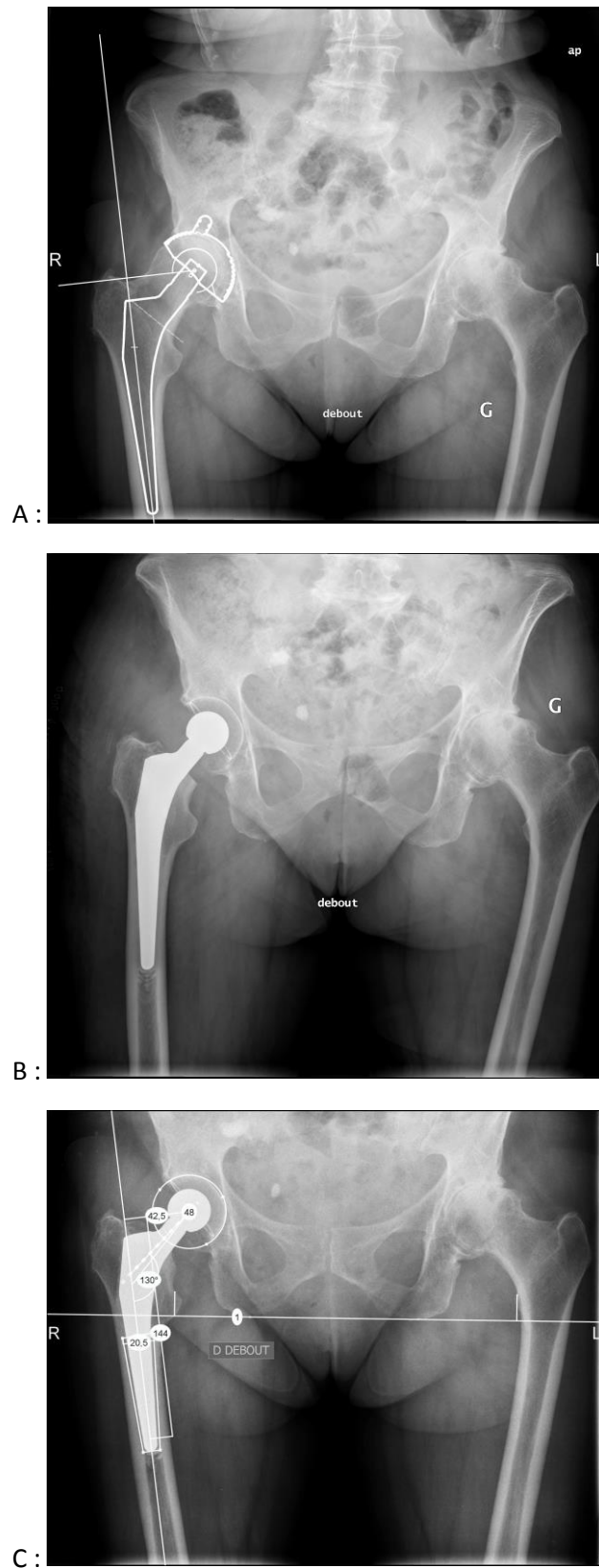


Figure 2: example showing a patient who had a standard stem: A: preoperative X-ray with planification, B: early postoperative (3 months), C: late postoperative with measurement (2 years)

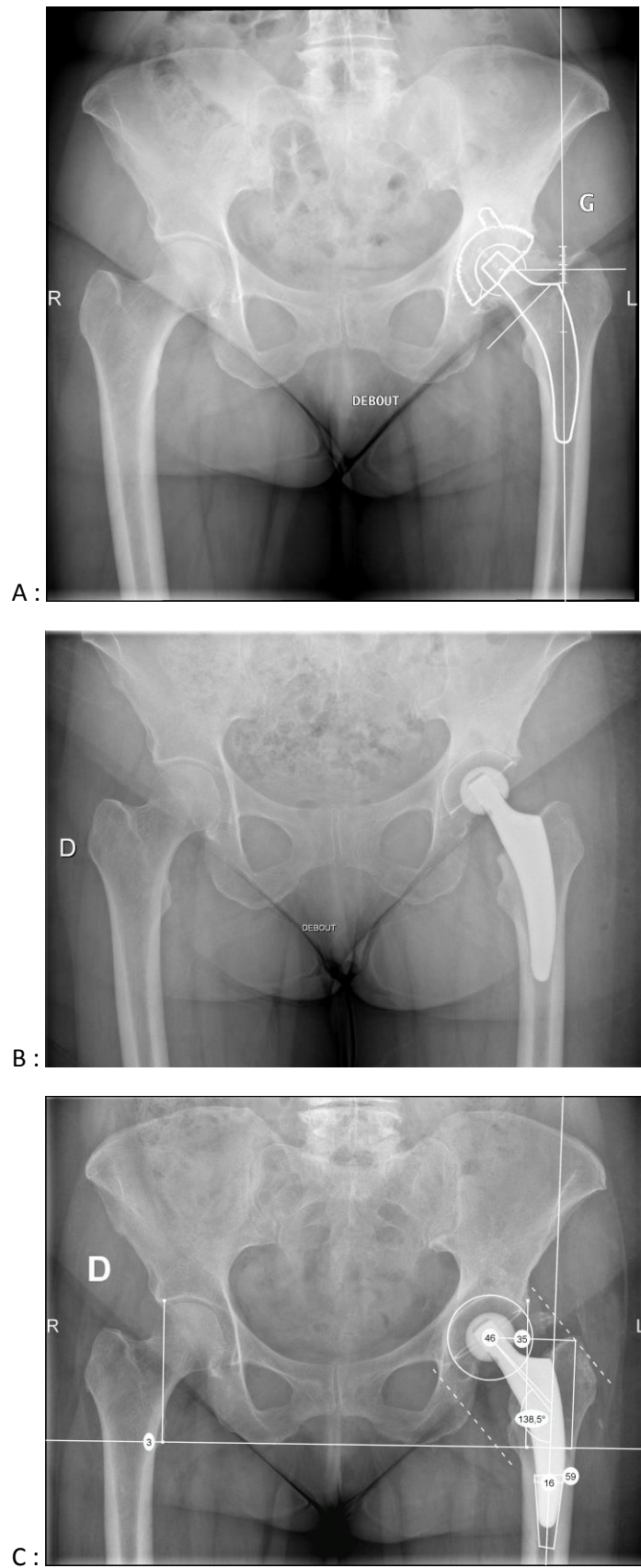


Figure 3: example showing a patient who had a short stem: A: preoperative X-ray with planification, B: early postoperative (1.5 month), C: late postoperative with measurement (4 years)

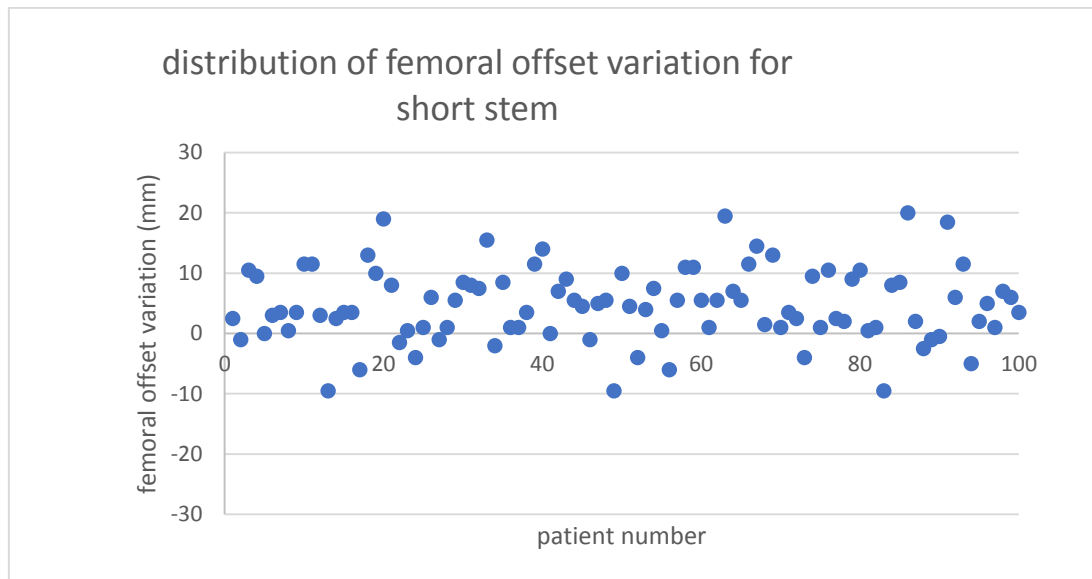


Figure 2 a: distribution of femoral offset variation for short stem

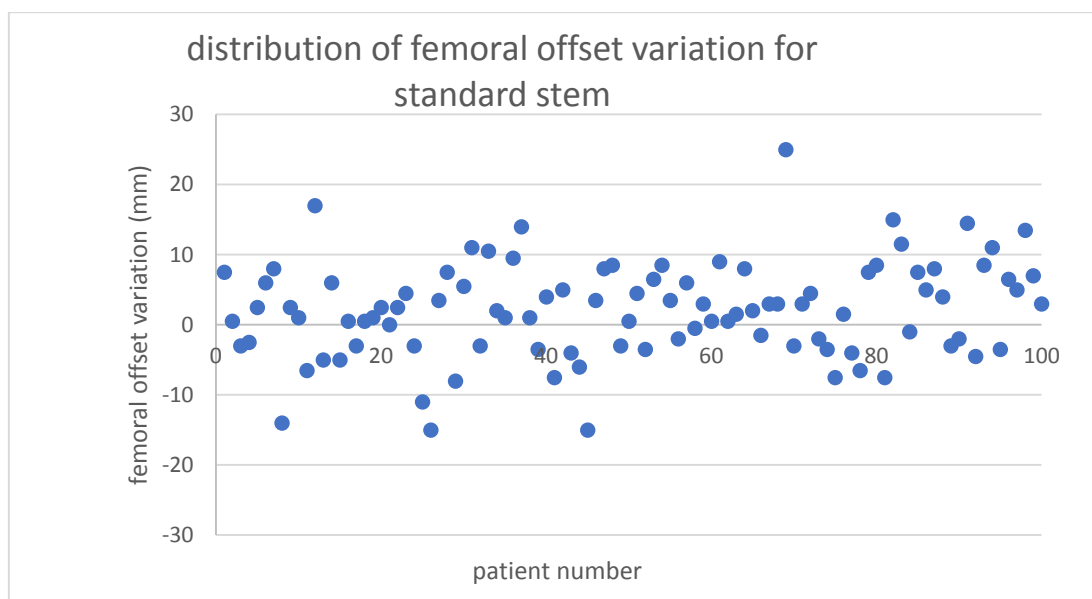


Figure 2 b: distribution of femoral offset variation for standard stem

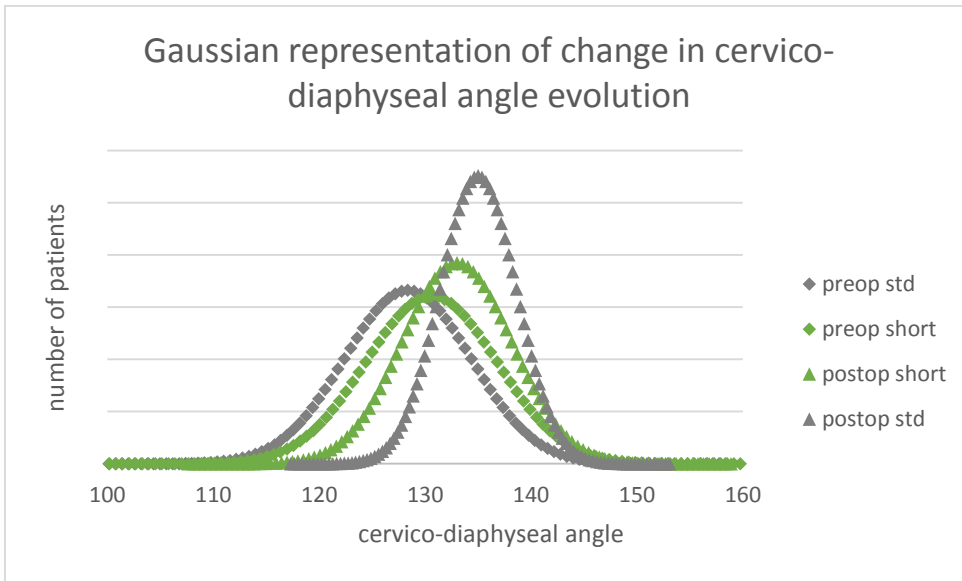


Figure 3:Change in cervico-diaphyseal angle