

MRI Atlas of the Human Deep Brain

Jean-Jacques Lemaire^{1*}, Antonio de Salles², Guillaume Coll¹, Youssef El Ouidi¹, Rémi Chaix¹, Jérôme Coste¹, Franck Durif³, Nikos Makris⁴, Ron Kikinis^{4,5,6}.

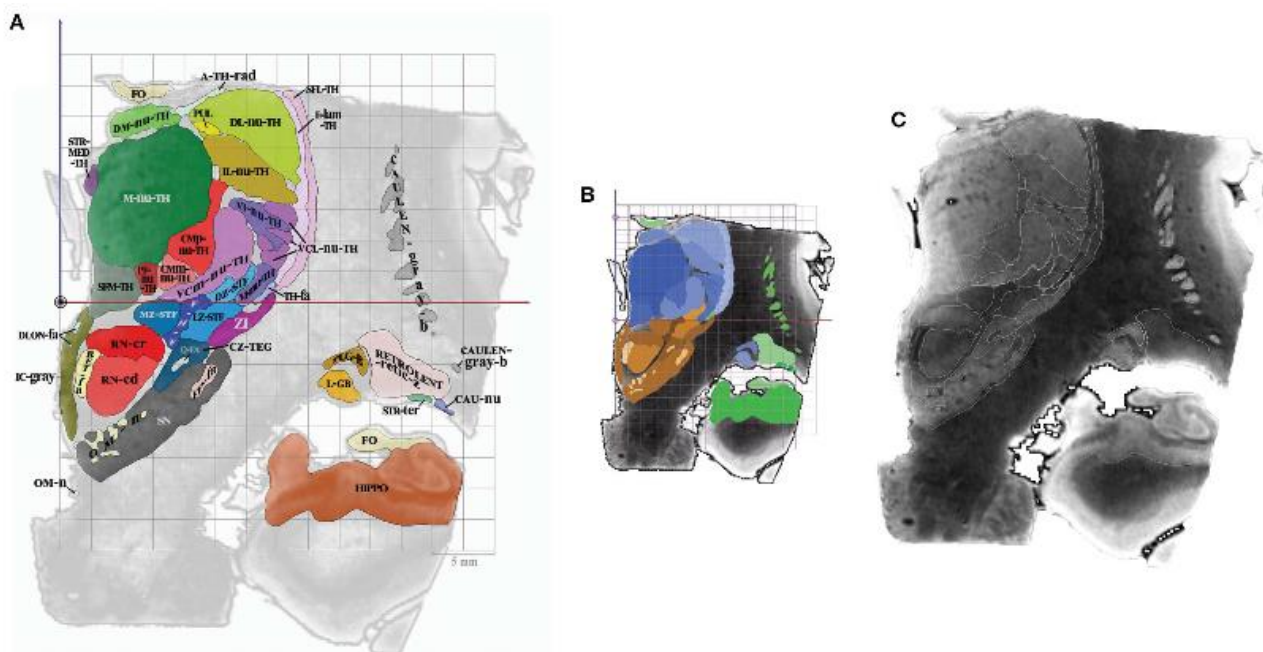
1. Service de Neurochirurgie, CHU Clermont-Ferrand, Université Clermont Auvergne, Centre National de la Recherche Scientifique, Engineering School SIGMA Clermont, Clermont-Ferrand, F-63000, France
2. HCOR NEUROSCIENCE, department of Neurosurgery and Department of Radiation oncology, São Paulo, Brazil
3. Service de Neurologie, CHU Clermont-Ferrand, Université Clermont Auvergne, Centre National de la Recherche Scientifique, Engineering School SIGMA Clermont, Clermont-Ferrand, F-63000, France
4. Harvard Medical School, Center for Morphometric Analysis, Massachusetts General Hospital, A. Martinos Center for Biomedical Imaging and Surgical planning Laboratory, Brigham and Women's Hospital, Boston, USA
5. Robert Grenes Distinguished Director of Biomedical Informatics, Brigham and Women's Hospital, Boston, USA
6. Computer Science Department, University of Bremen, Institutsleiter, Fraunhofer MEVIS, Bremen, Germany

*. Orator

Abstract

Mastering detailed anatomy of the human deep brain in clinical neurosciences is challenging. Although numerous pioneering works have gathered a large dataset of structural and topographic information, it is still difficult to transfer this knowledge into practice, even with advanced magnetic resonance imaging techniques. Thus, classical histological atlases continue to be used to identify structures for stereotactic targeting in functional neurosurgery. Physicians mainly use these atlases as a template co-registered with the patient's brain. However, it is possible to directly identify stereotactic targets on MRI scans, enabling personalized targeting. In order to help clinicians directly identify deep brain structures relevant to present and future medical applications, we built a volumetric MRI atlas of the deep brain (MDBA) on a large scale (infra millimetric). Twelve hypothalamic, 39 subthalamic, 36 telencephalic, and 32 thalamic structures were identified, contoured, and labeled. Nineteen coronal, 18 axial, and 15 sagittal MRI plates were created. Although primarily designed for direct labeling, the anatomic space was also subdivided in twelfths of AC-PC distance, leading to proportional scaling in the coronal, axial, and sagittal planes. This extensive work is now available to clinicians and neuroscientists, offering another representation of the human deep brain ([https:// hal.archives-ouvertes.fr/](https://hal.archives-ouvertes.fr/) [hal-02116633]). The atlas may also be used by computer scientists who are interested in deciphering the topography of this complex region.

Illustration



Legend of the figure

(A) Colored surfaces and acronyms, plate CR8 (millimeter scale), the ACPC line is depicted as a black circle.

(B) Same plate, colors are specified according to subregions (proportional and millimeter scales); thalamus (blue gradation), subthalamus (brown gradation) and telencephalon (green gradation).

(C) Same plate, MRI slice and white contours of structures (no scale)

References

1. Jean-Jacques Lemaire, Antonio de Salles, Guillaume Coll, Youssef El Ouidih, Rémi Chaix, *et al.* MRI Atlas of the Human Deep Brain. *Frontiers in Neurology*, Frontiers, 2019, 10, pp.851. doi: 10.3389/fneur.2019.00851.

HAL Id: hal-02191252 (<https://hal.uca.fr/hal-02191252>)

2. Jean-Jacques Lemaire. MRI Atlas of the Human Deep Brain. 2019. hal-02116633

HAL Id: hal-02116633 (<https://hal.uca.fr/hal-02116633>)