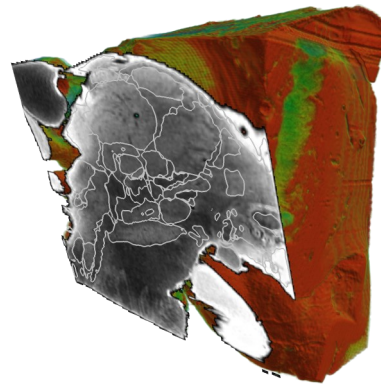

MRI ATLAS OF THE HUMAN DEEP BRAIN

Jean-Jacques Lemaire, MD, PhD, neurosurgeon, University Hospital of Clermont-Ferrand,
Université Clermont Auvergne, CNRS, SIGMA, France



This work is licensed under the Creative Commons Attribution-NonCommercial-NoDerivatives 4.0 International License. To view a copy of this license, visit <http://creativecommons.org/licenses/by-nc-nd/4.0/> or send a letter to Creative Commons, PO Box 1866, Mountain View, CA 94042, USA.

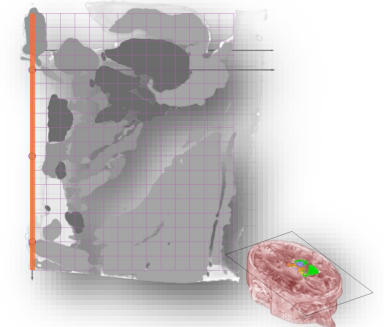
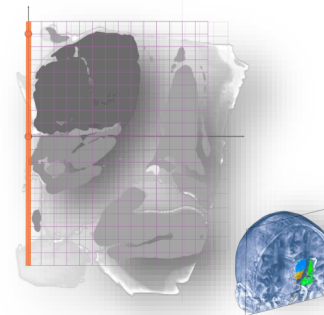
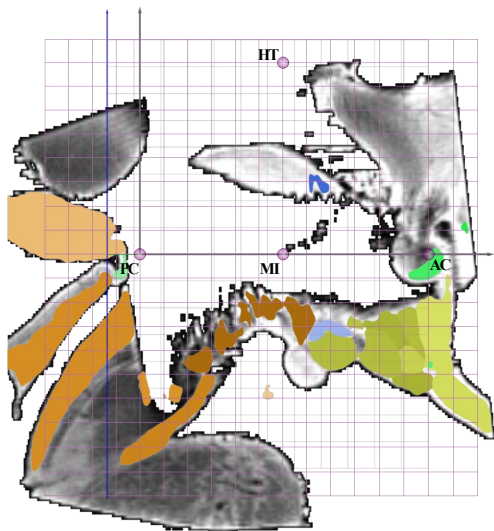
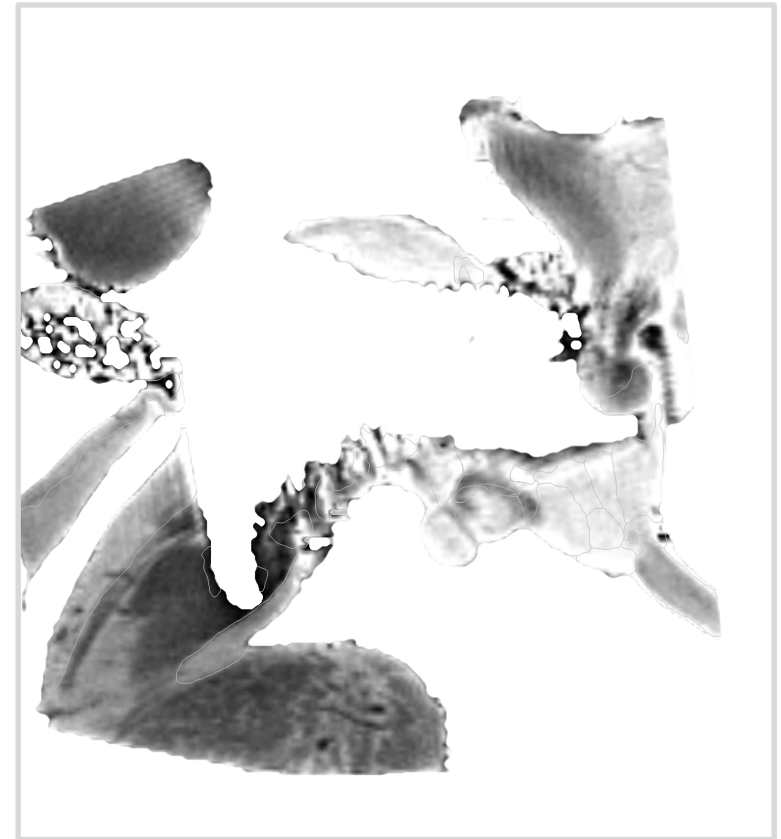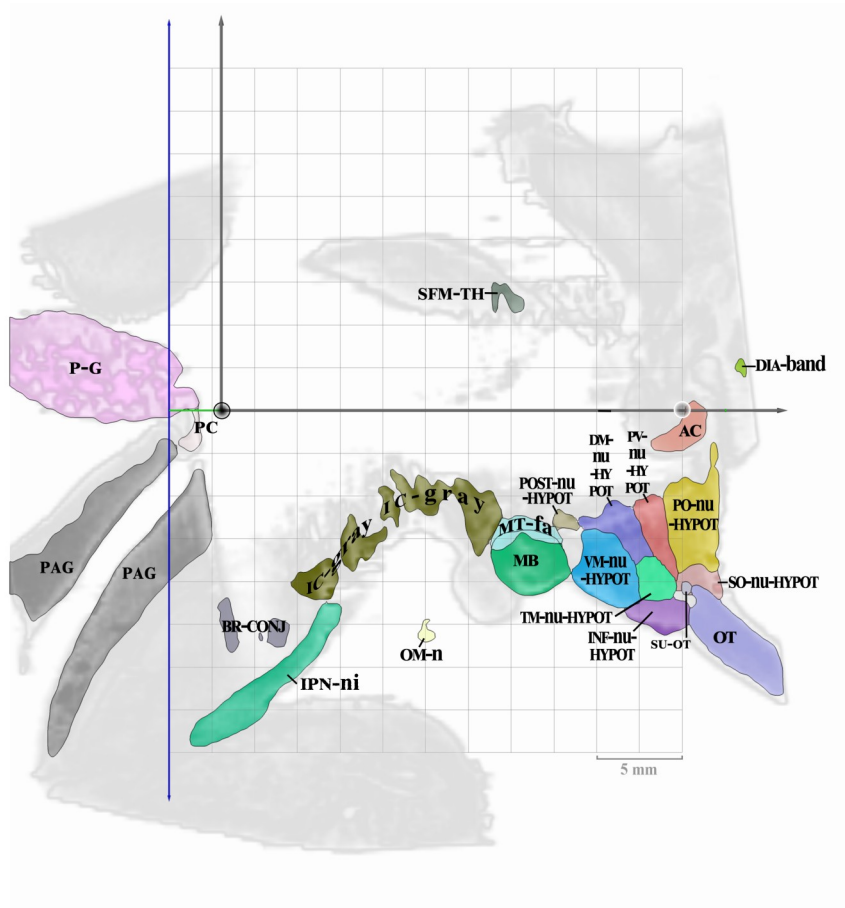
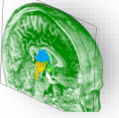


SAGITTAL PLATES

February 2019

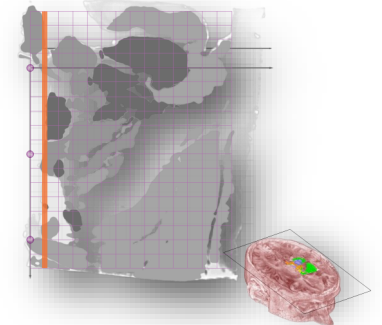
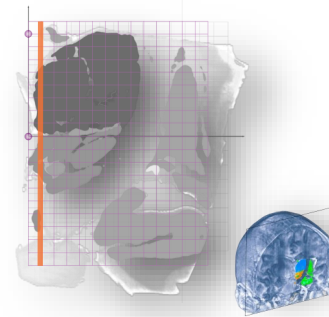
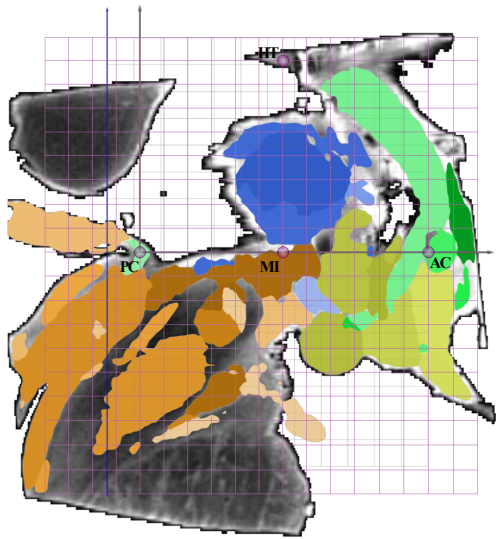
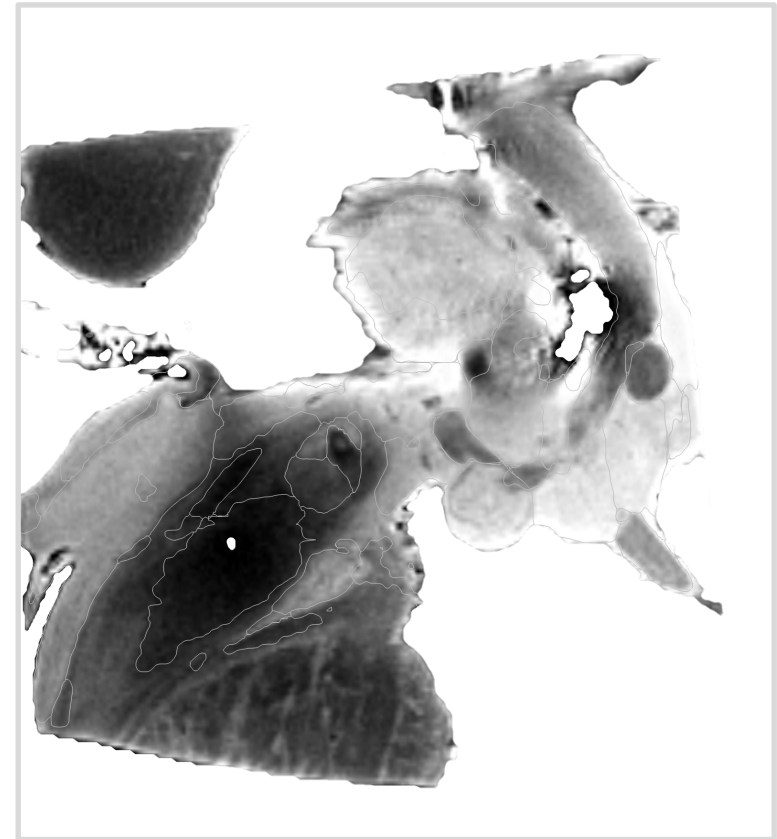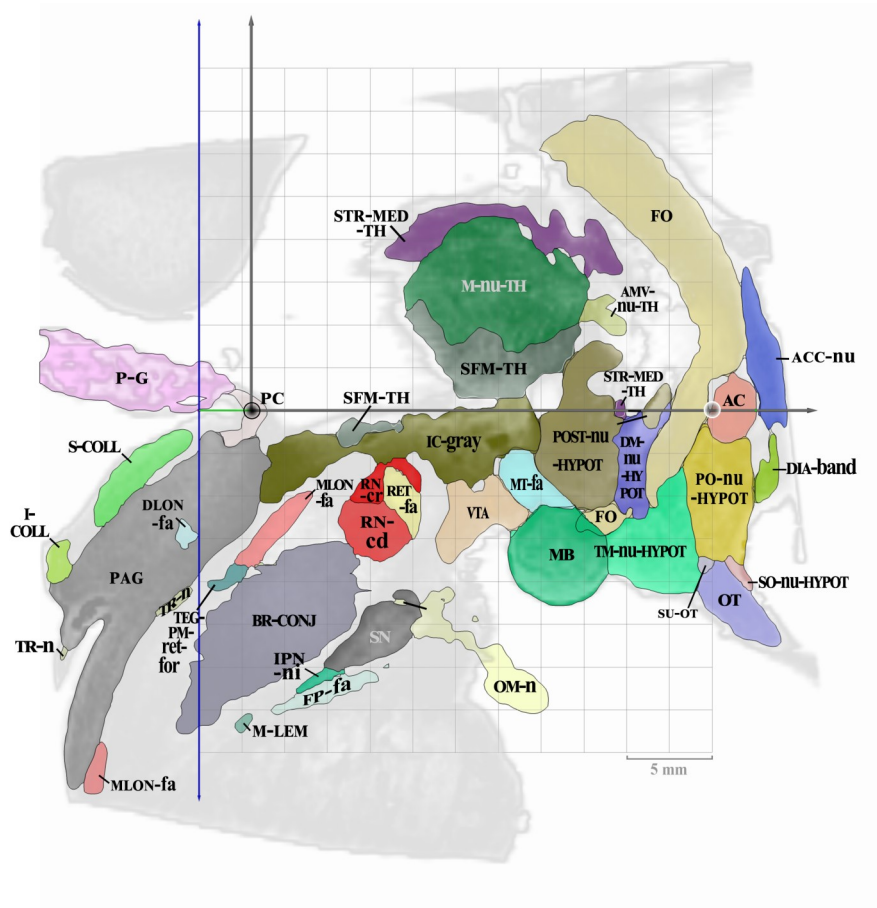
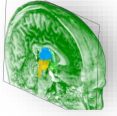
S0

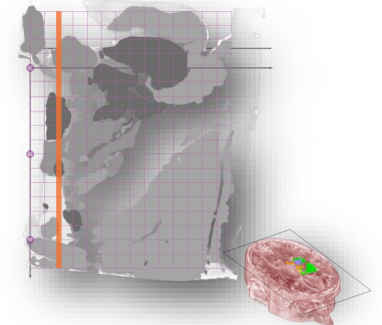
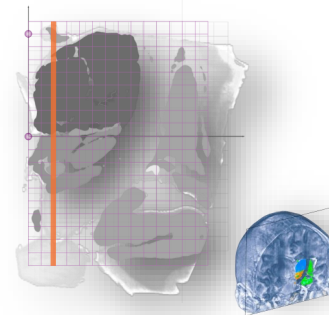
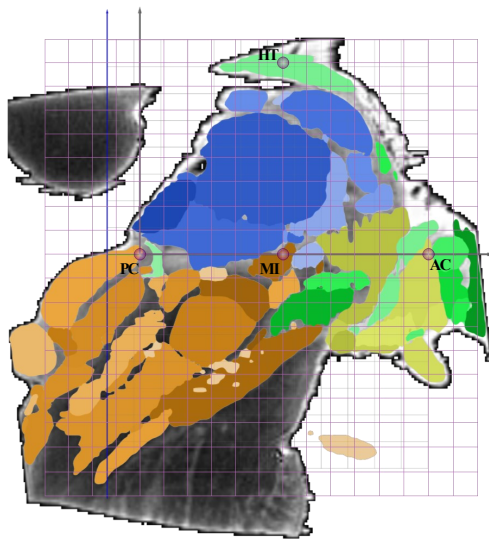
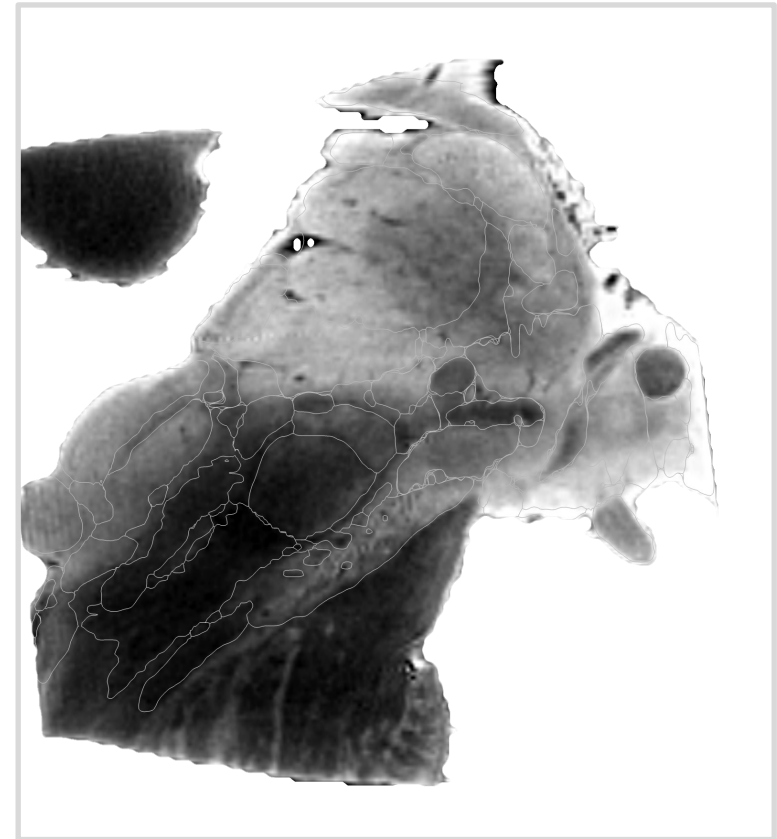
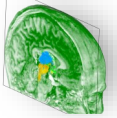
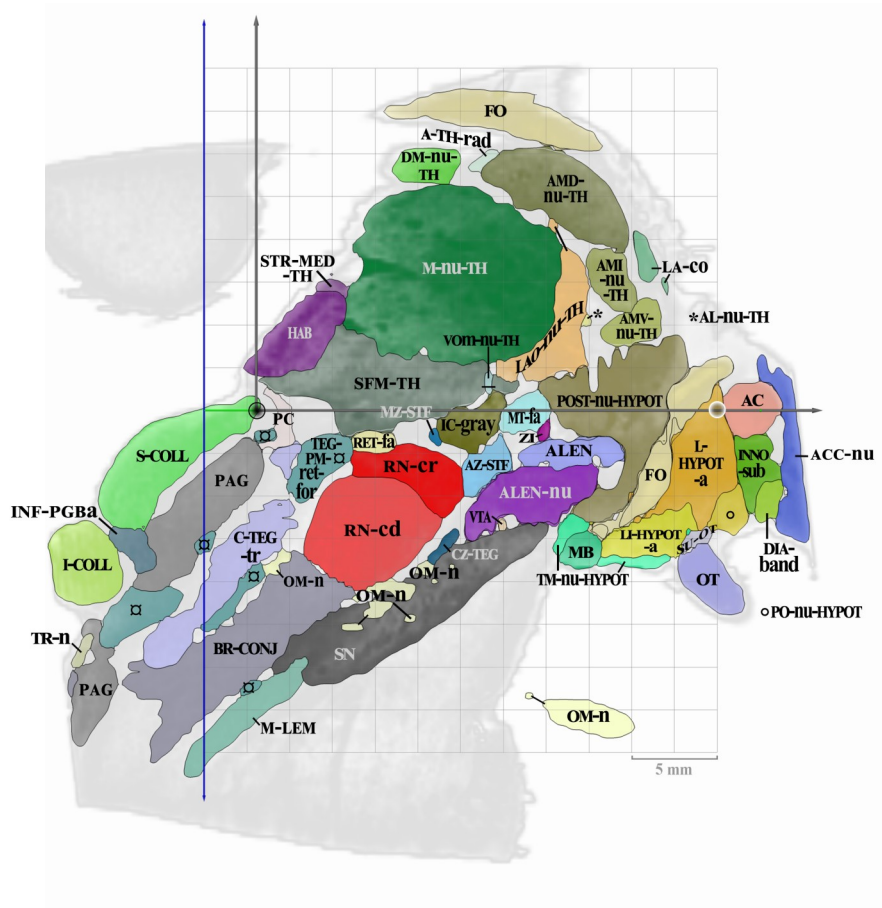
Sagittal MRI slice going through ACPC

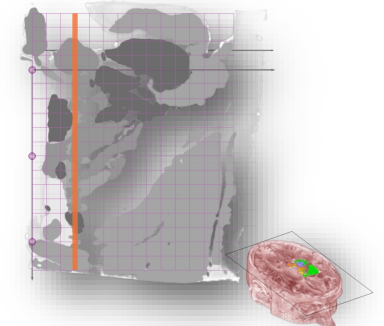
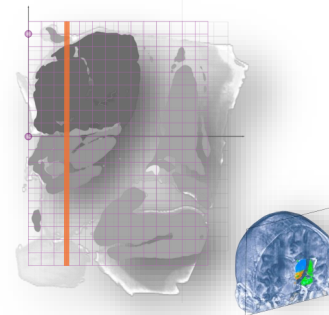
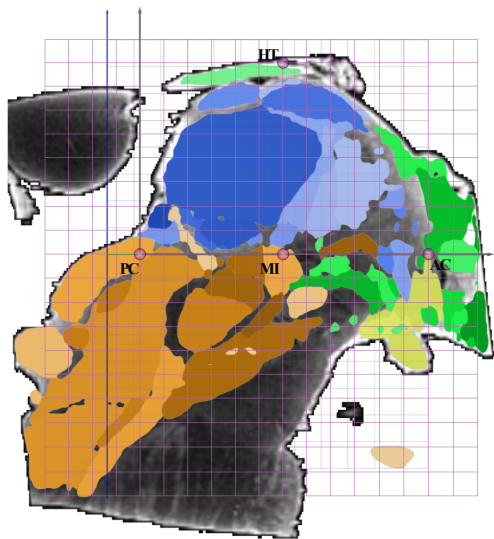
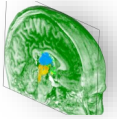
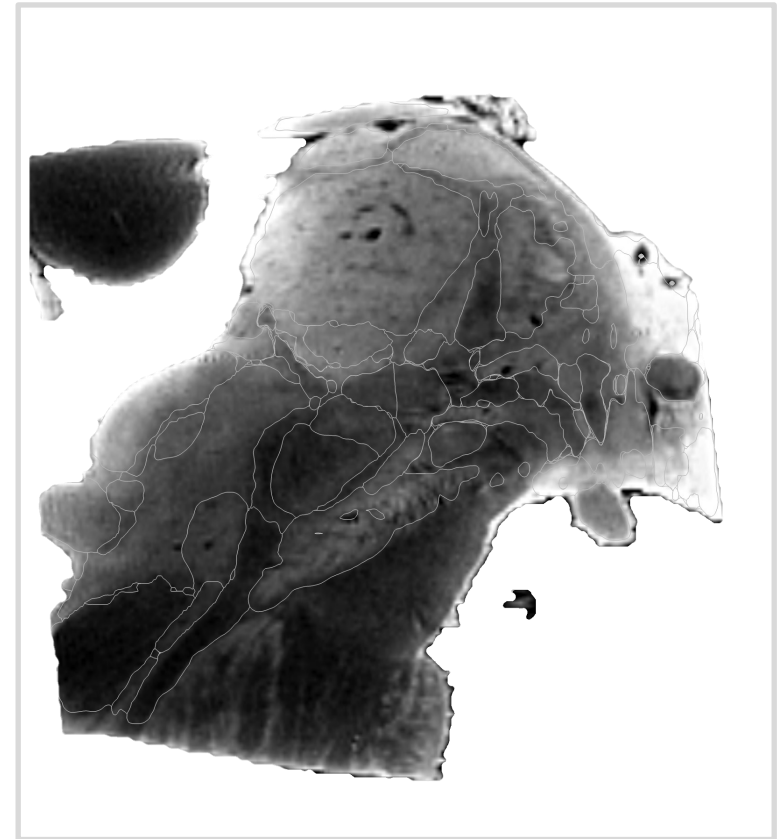
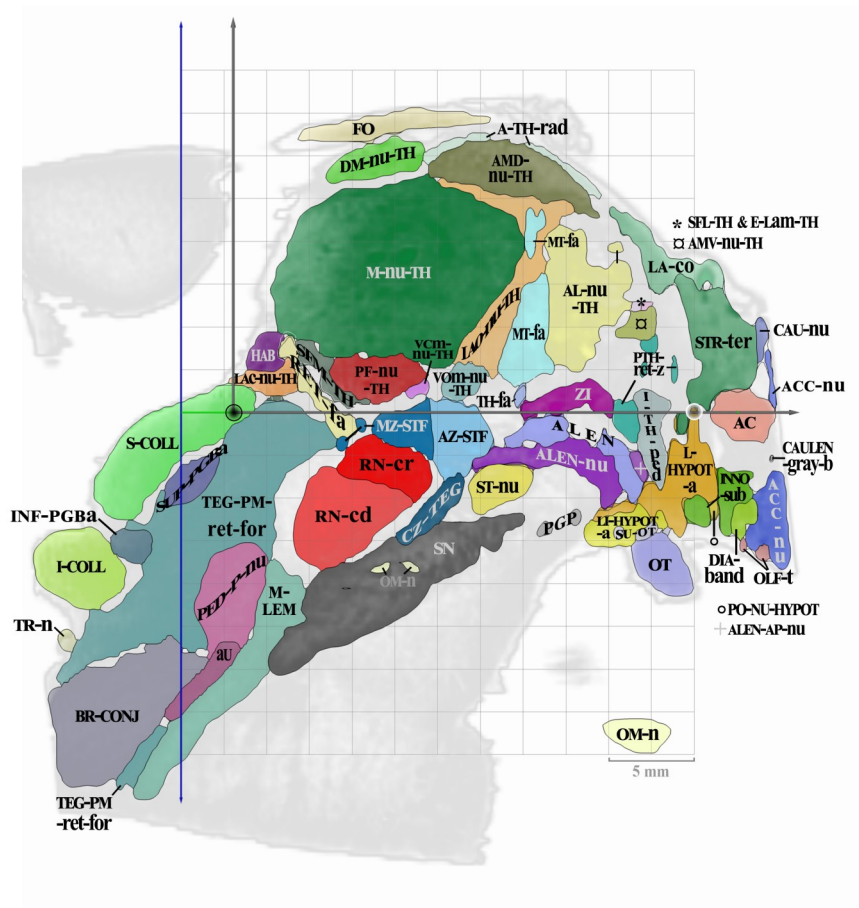


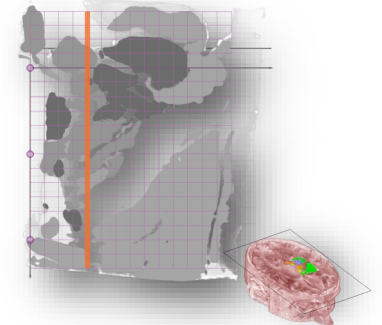
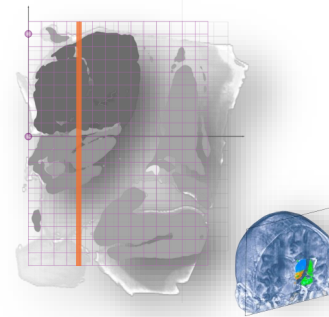
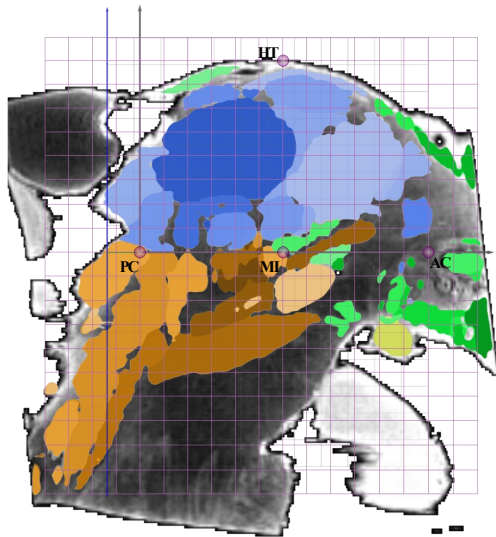
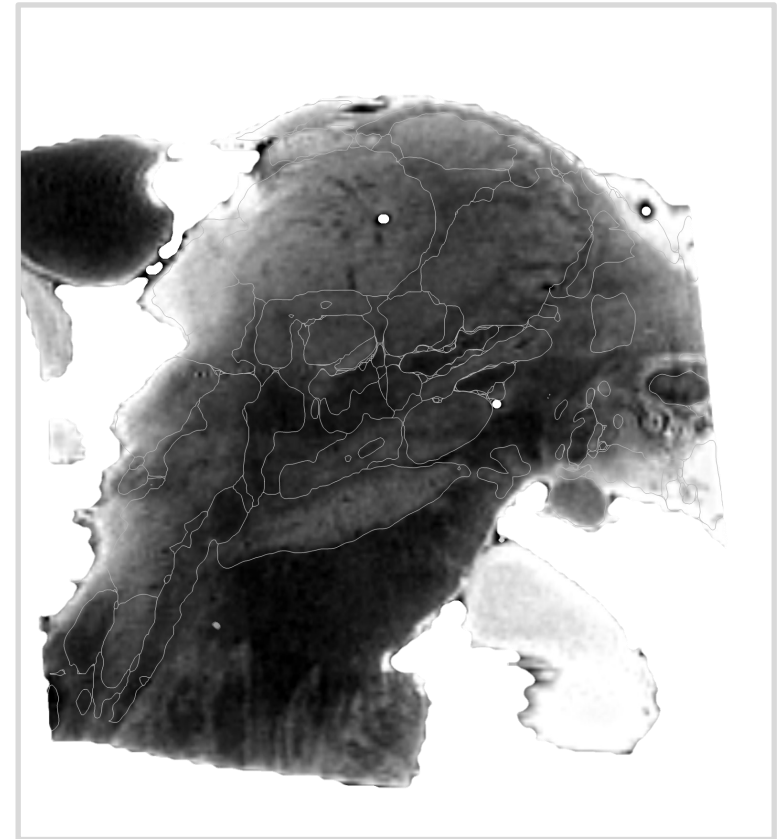
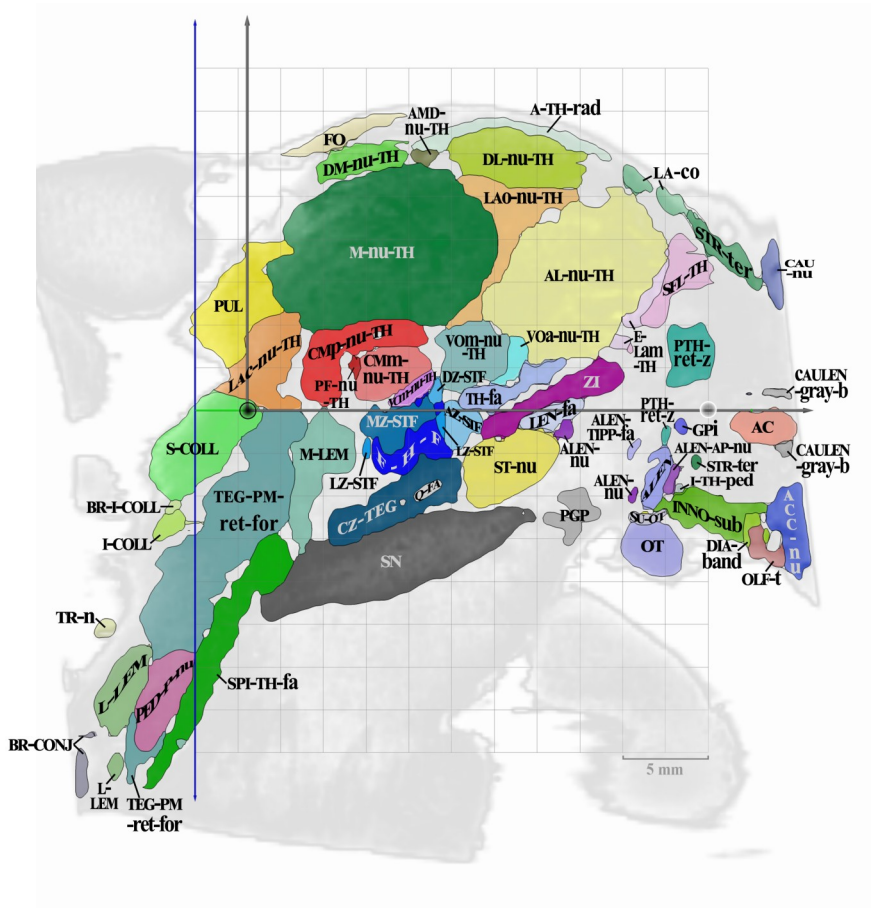
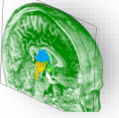
S1

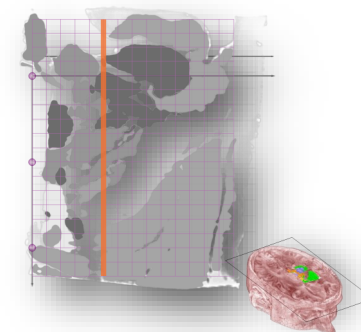
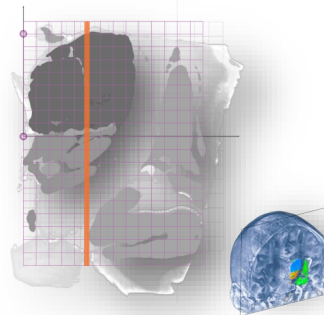
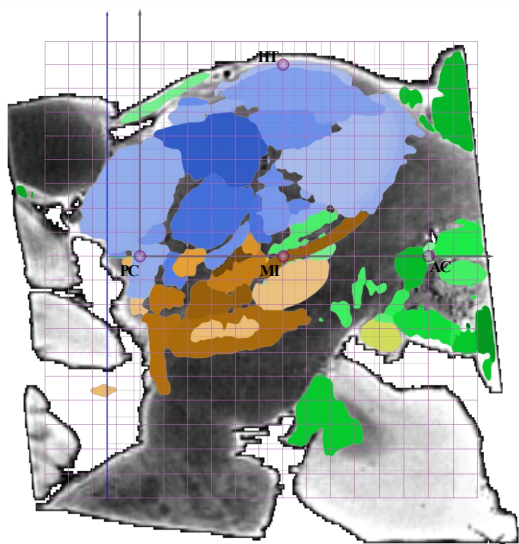
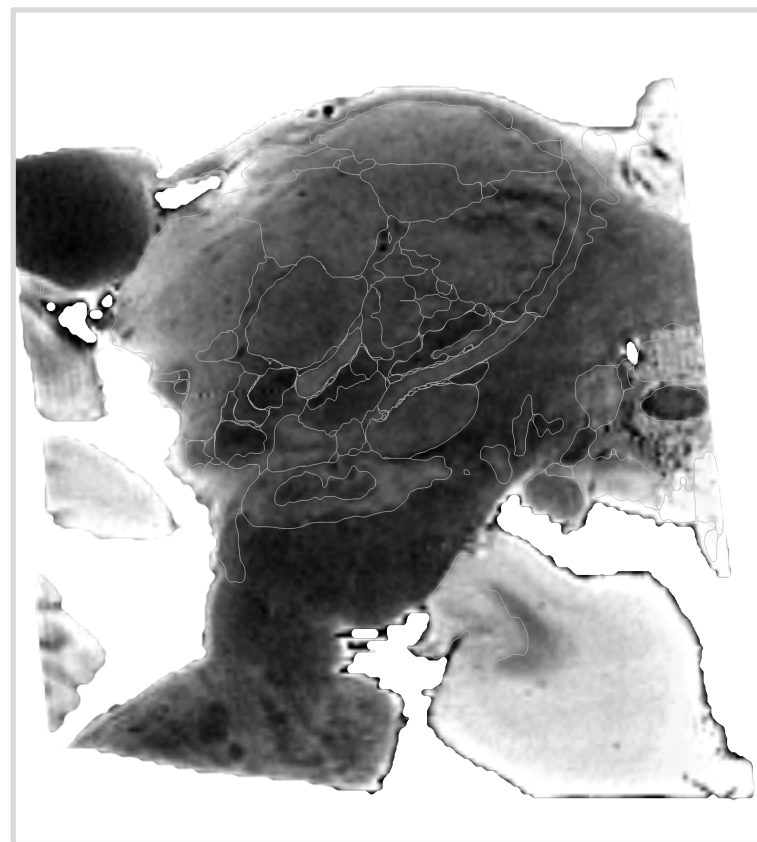
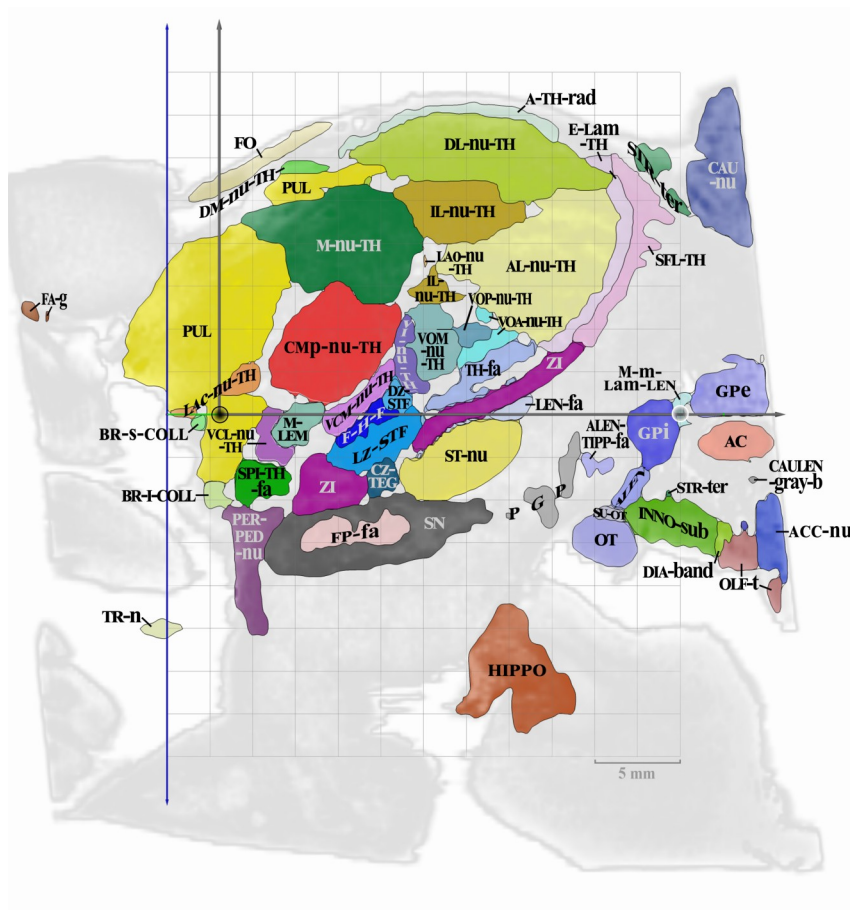
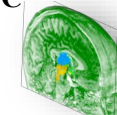
Sagittal MRI slice 2.3 mm lateral to ACPC

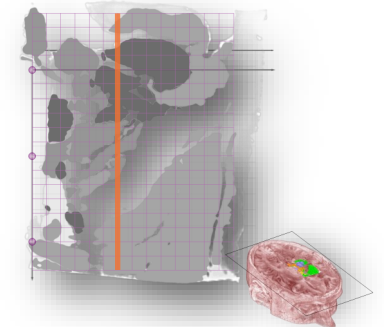
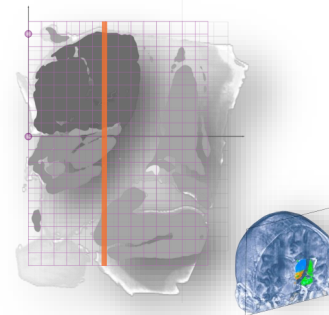
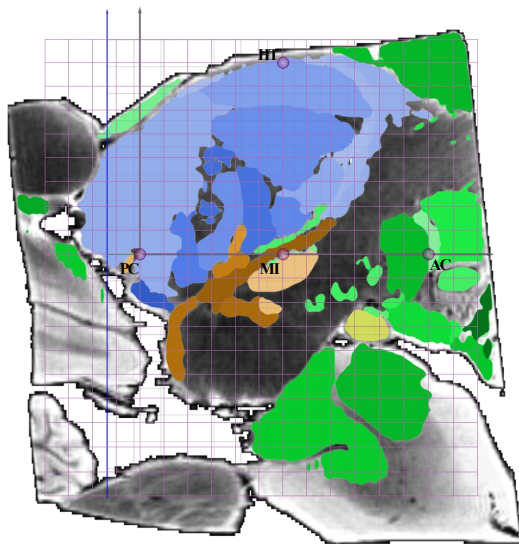
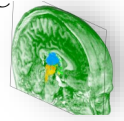
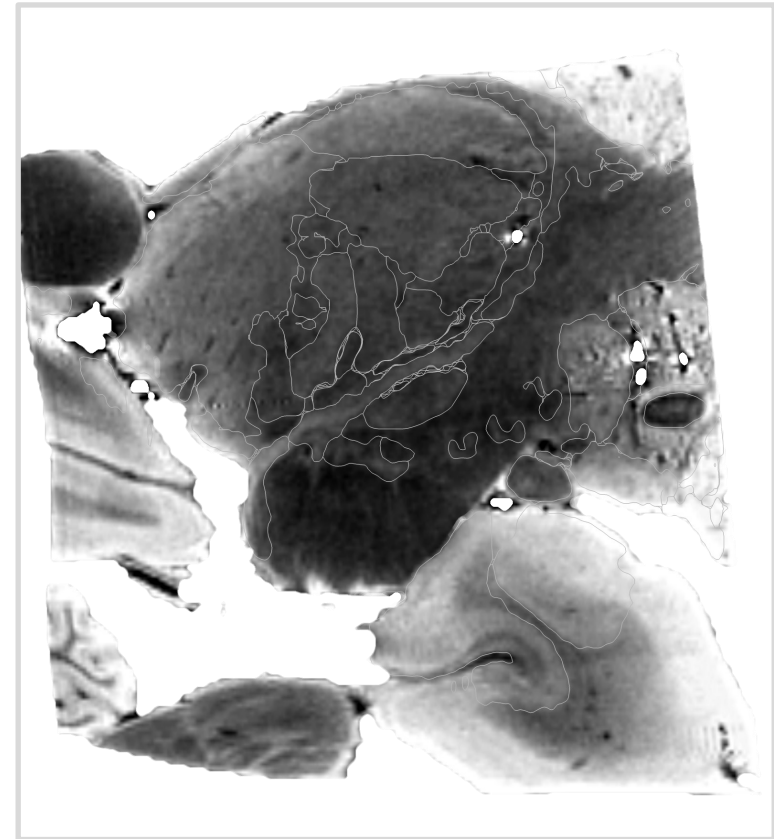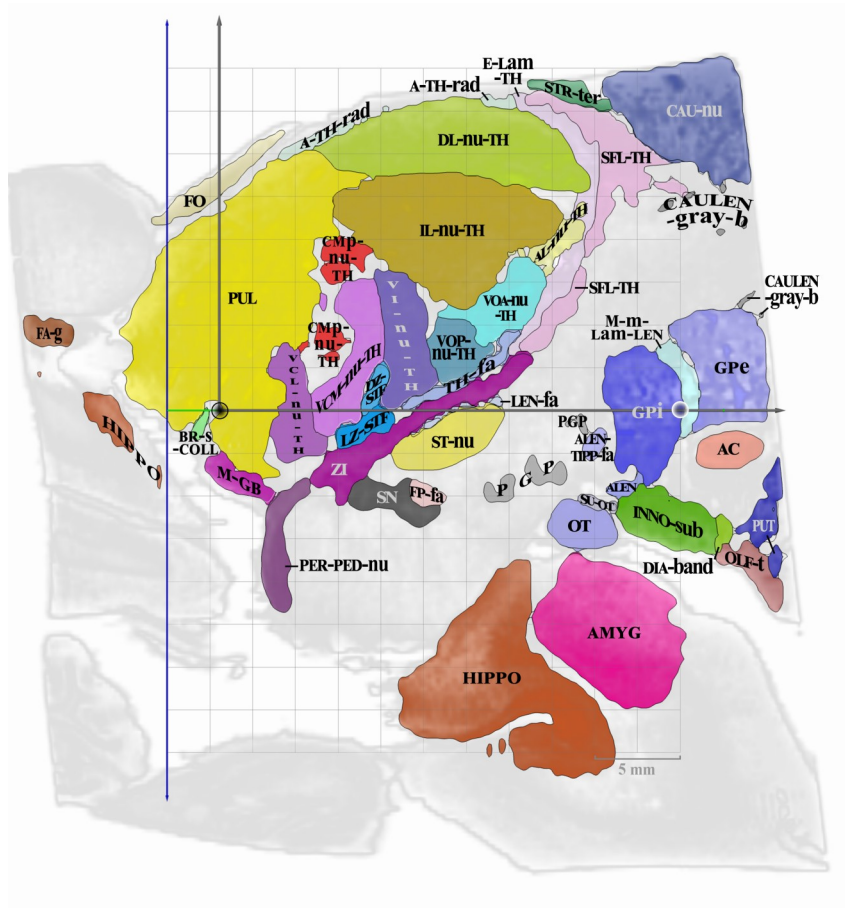


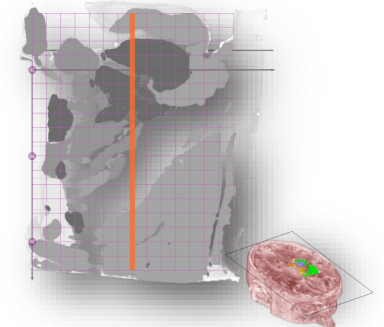
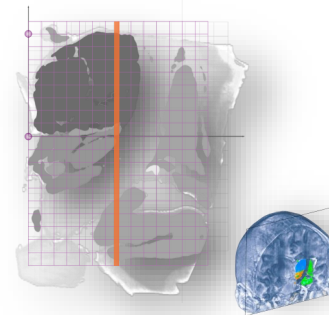
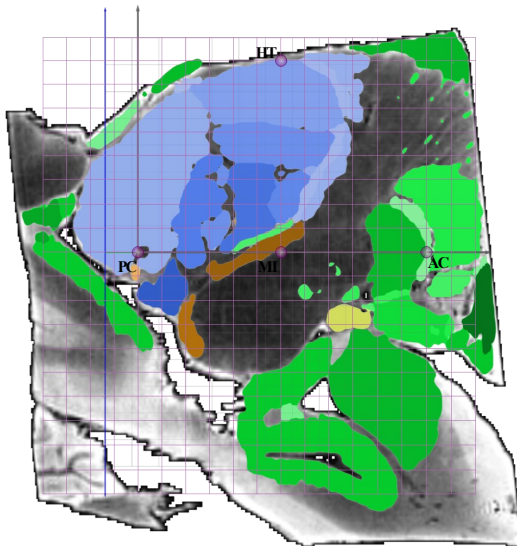
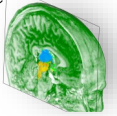
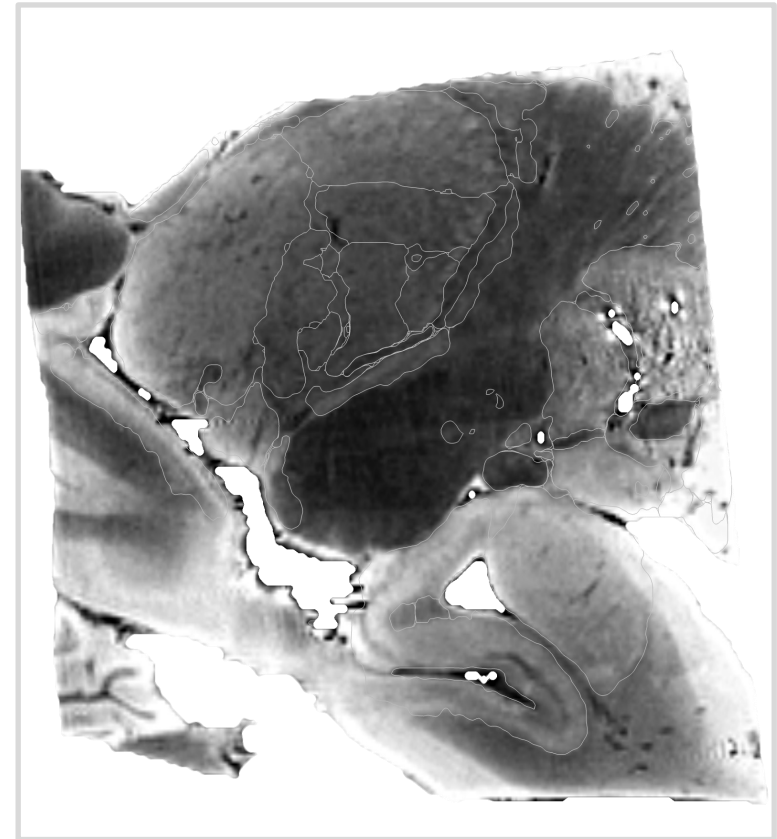
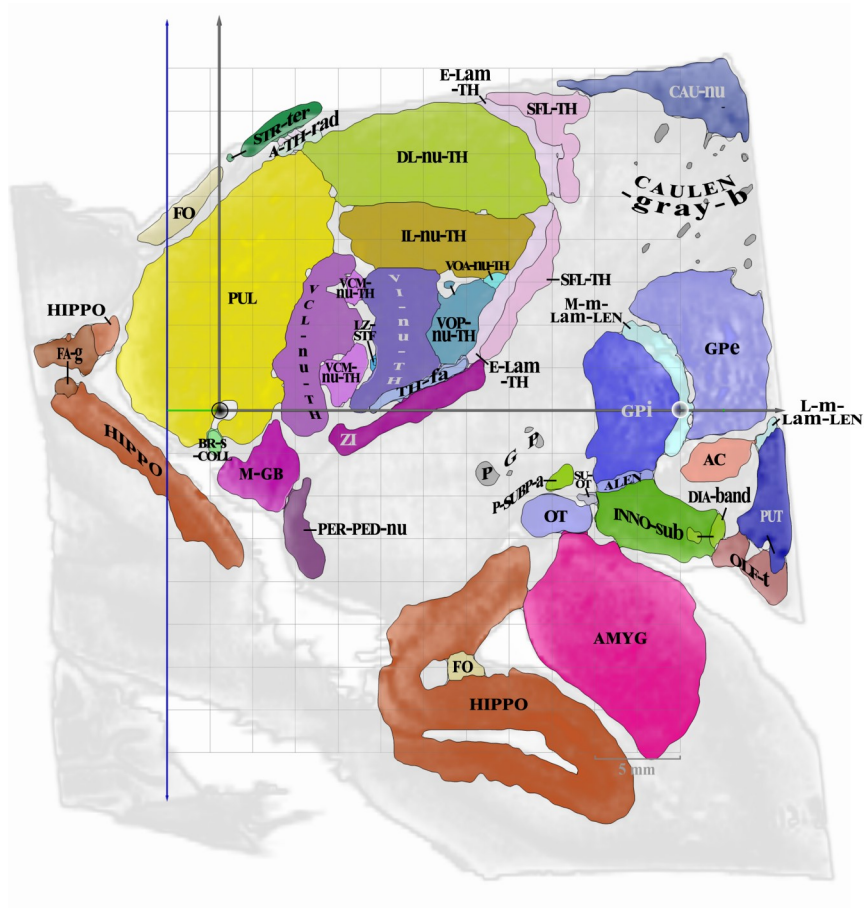


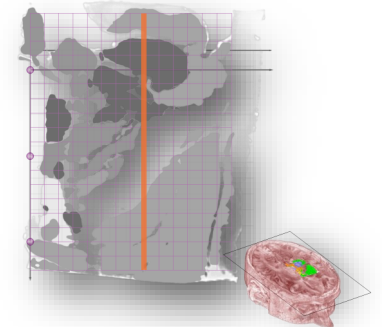
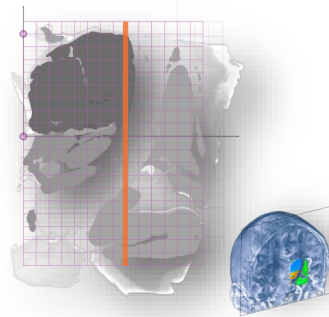
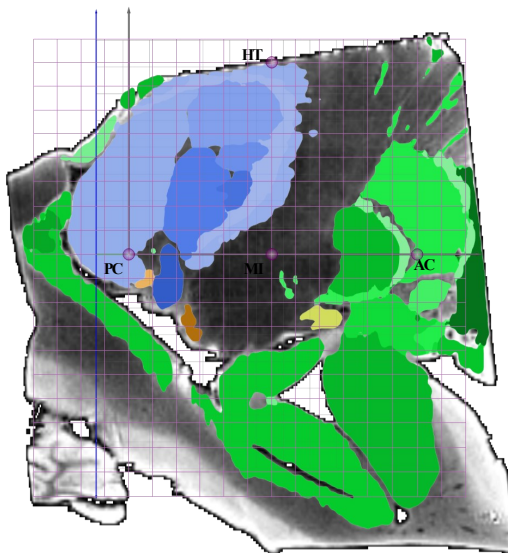
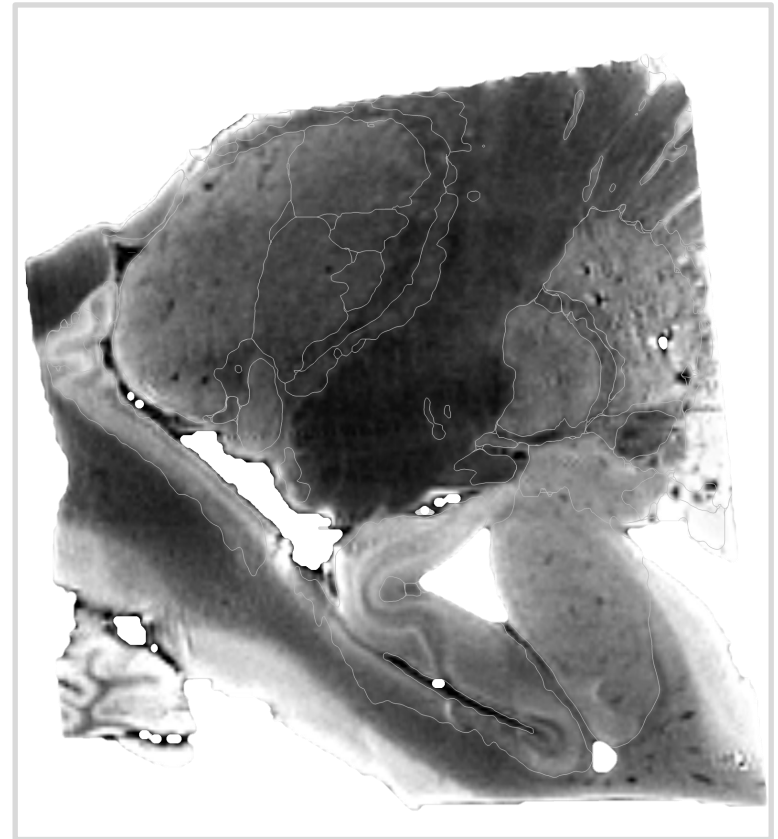
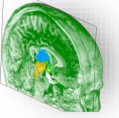
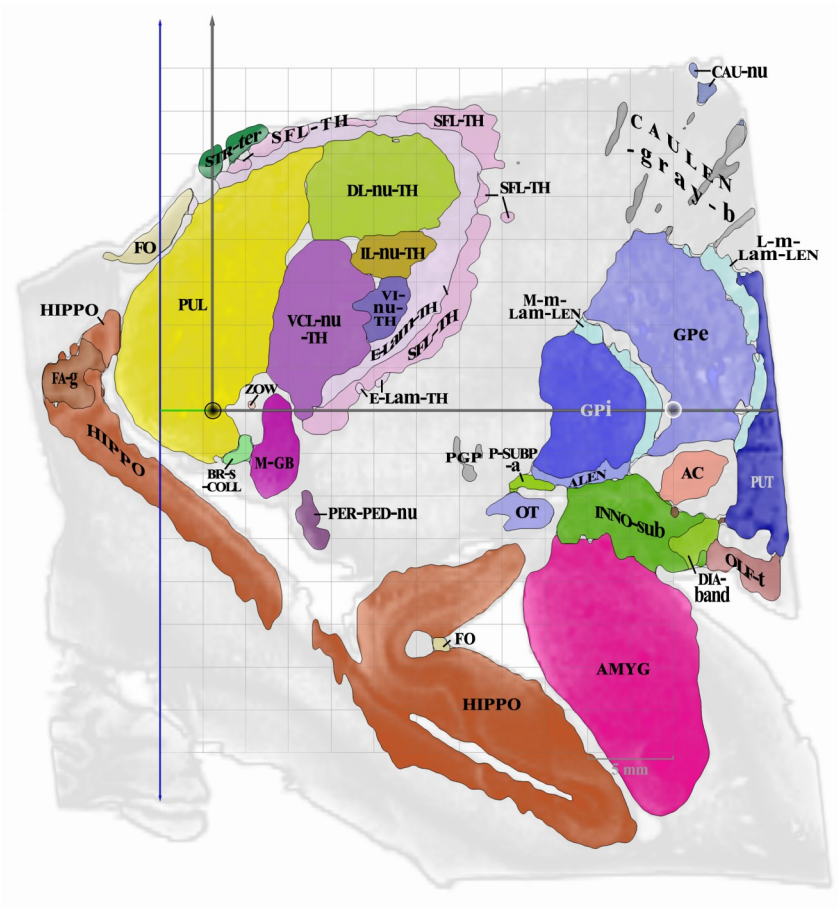


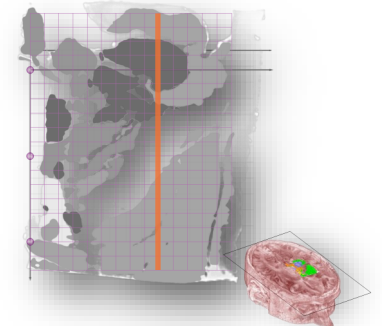
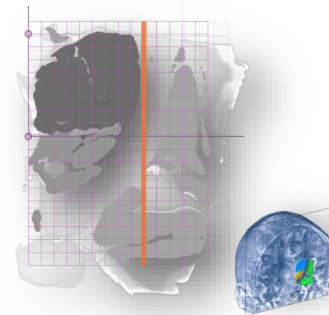
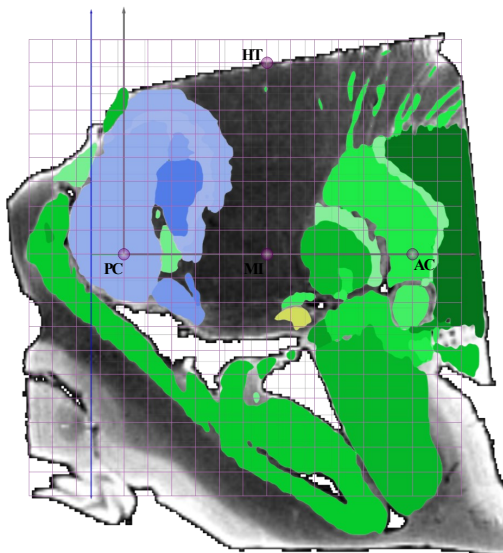
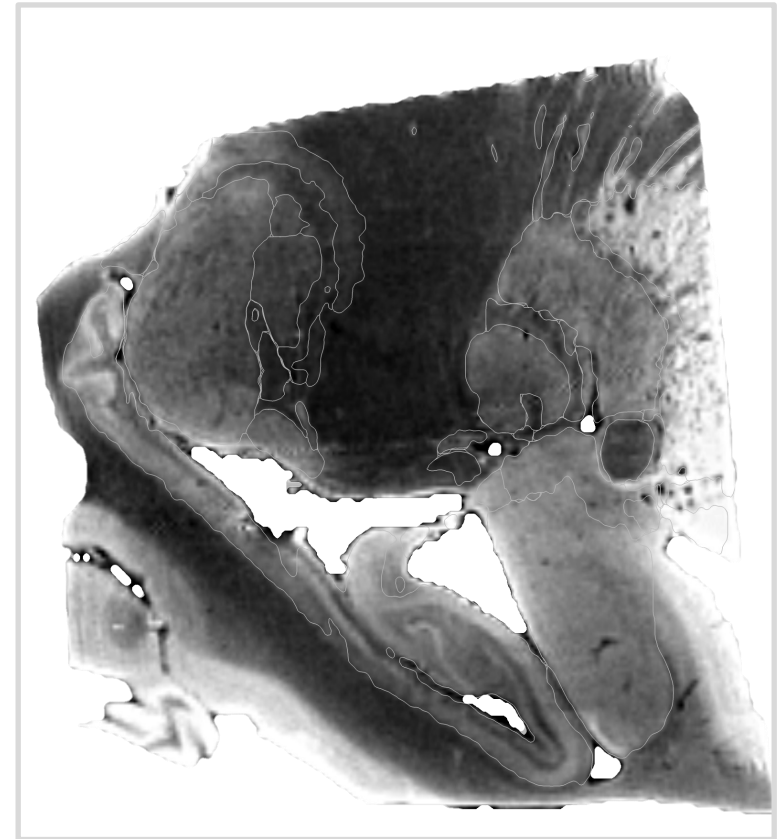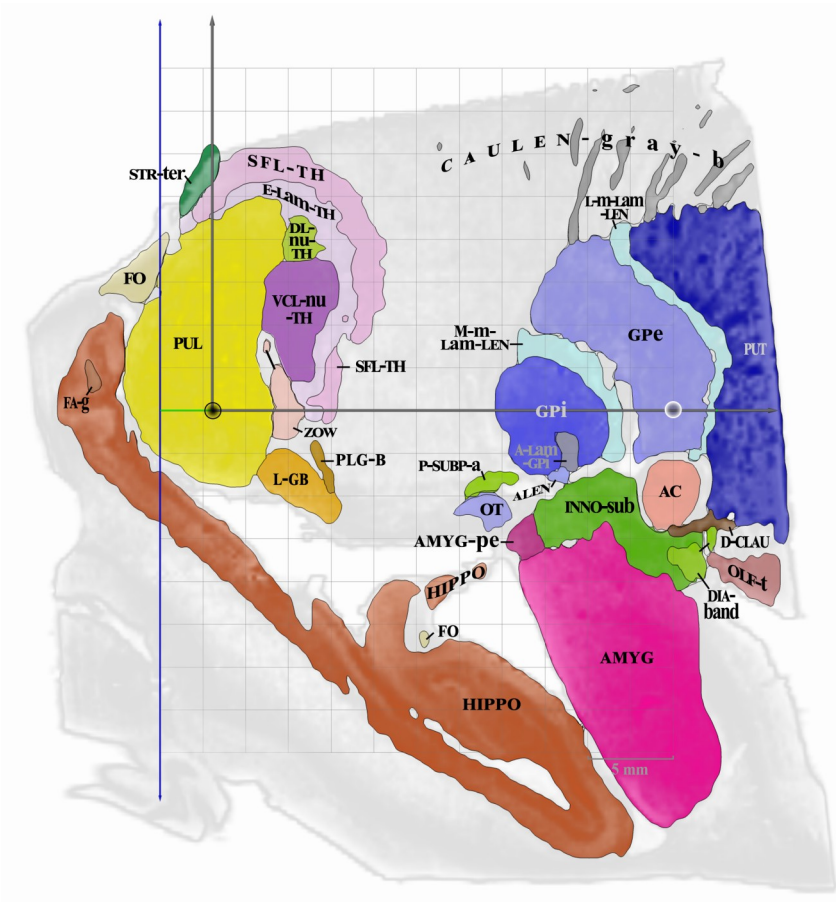
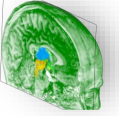


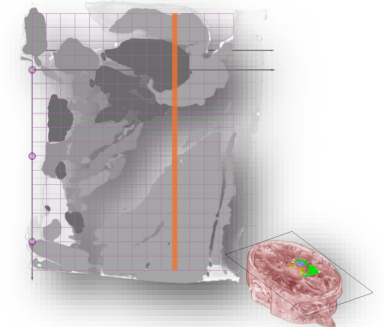
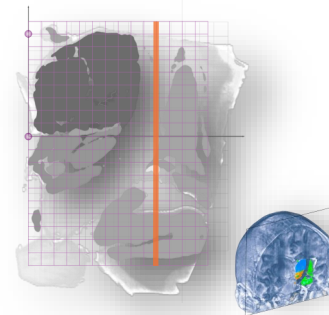
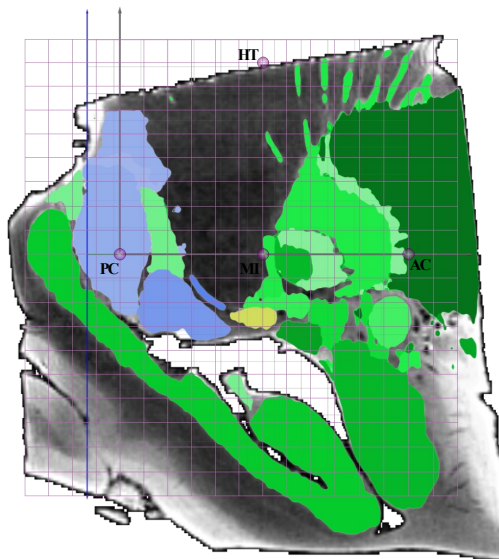
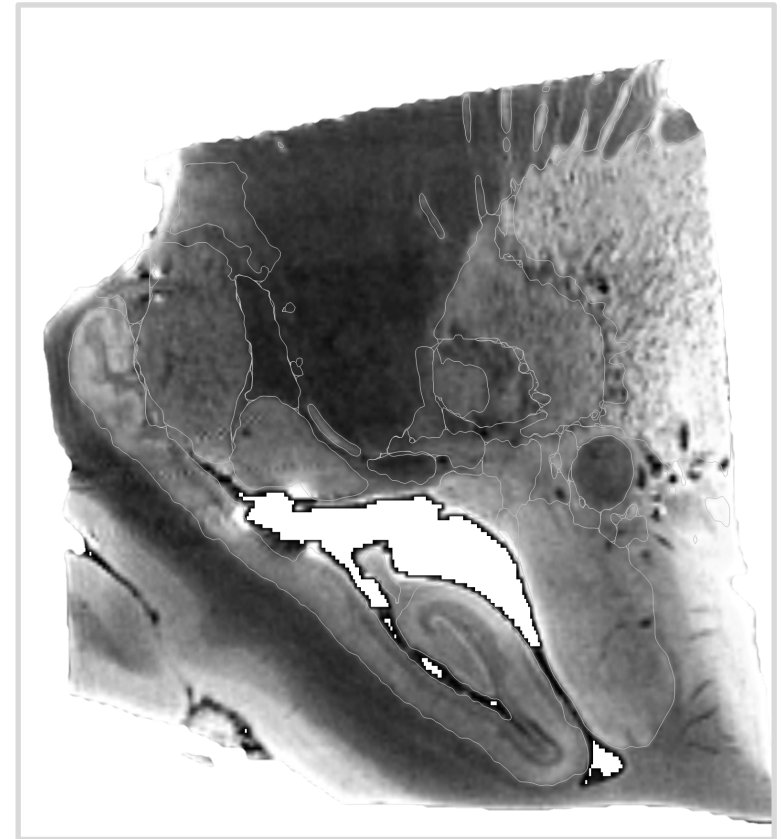
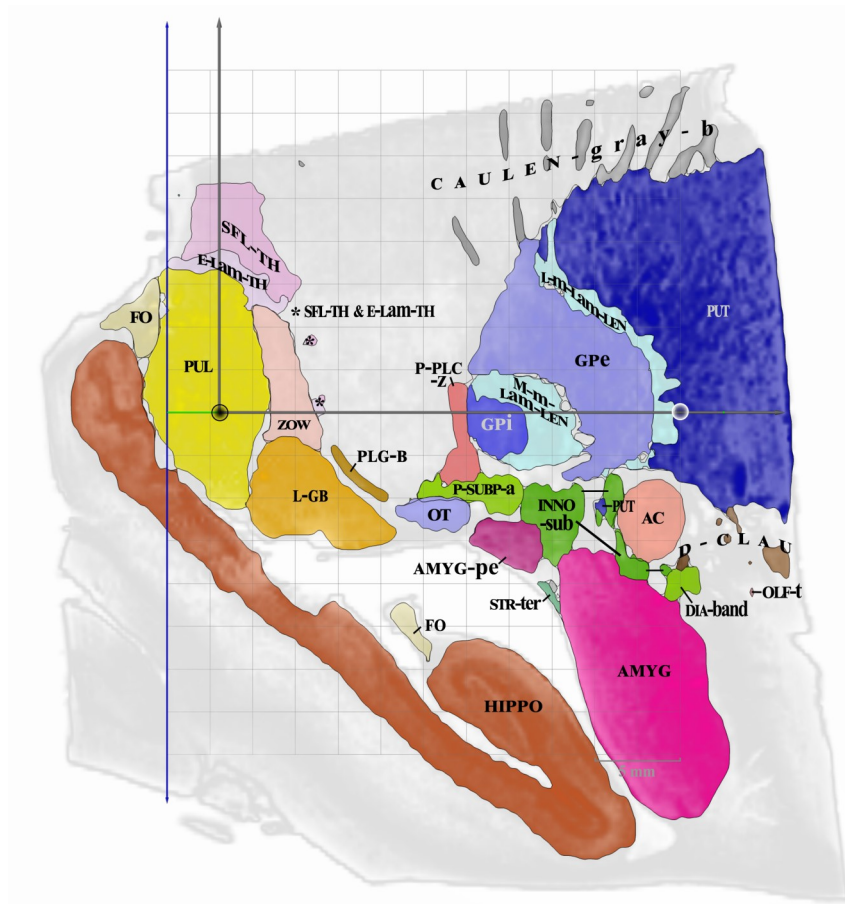
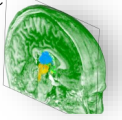


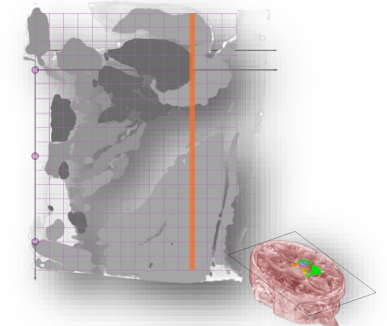
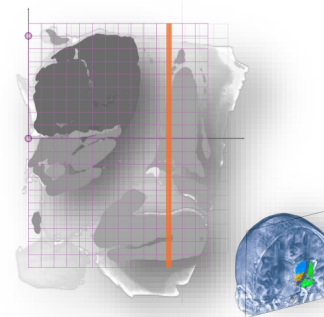
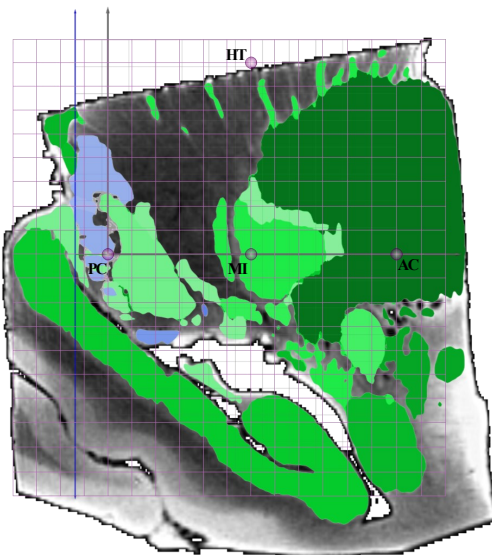
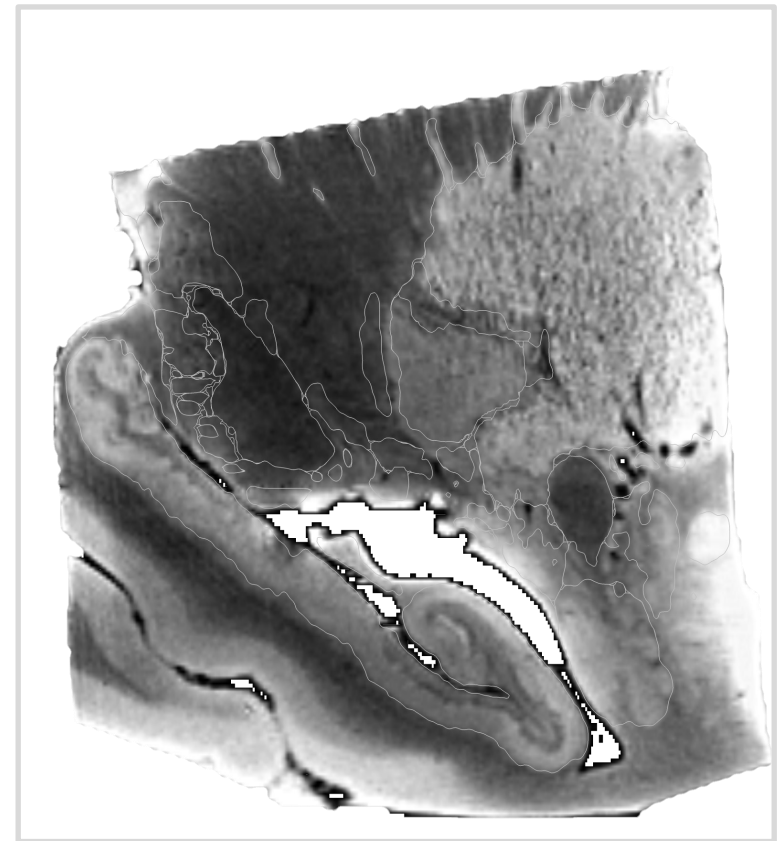
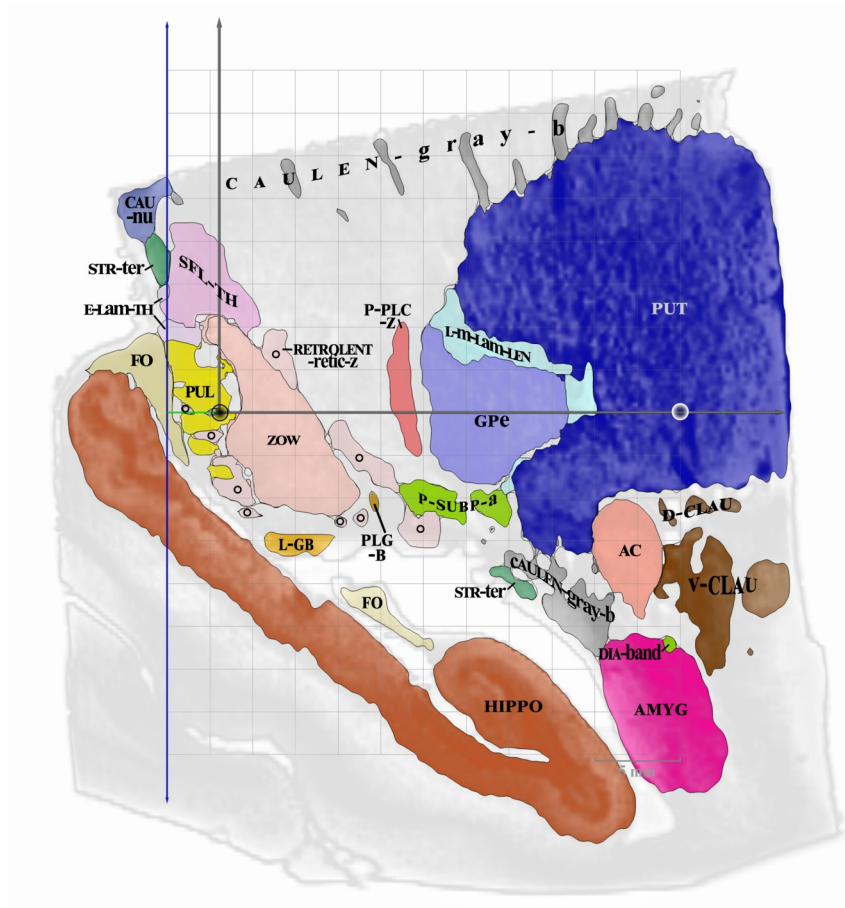
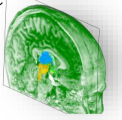


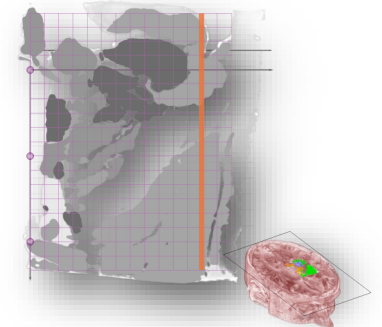
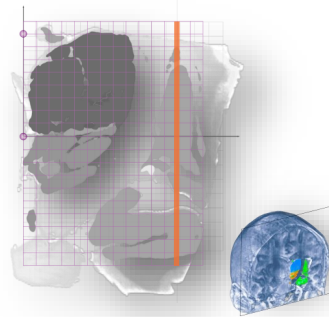
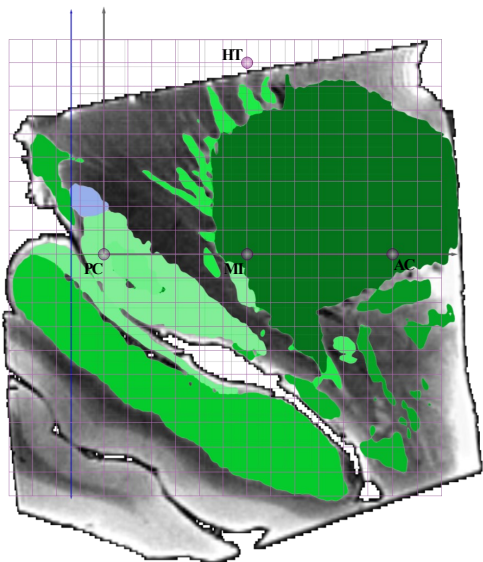
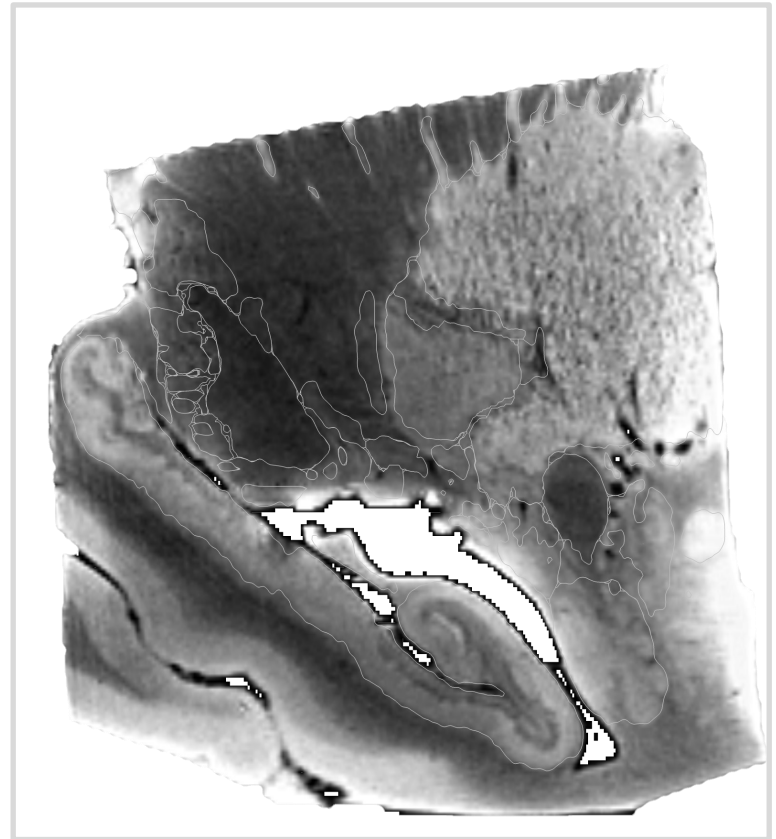
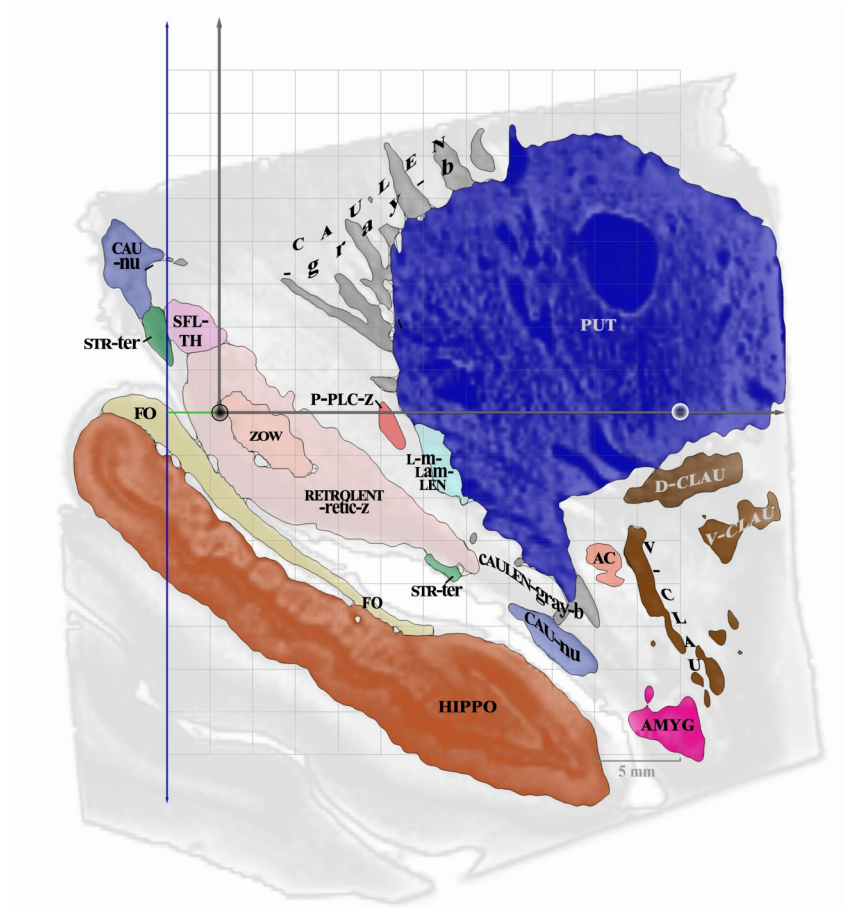
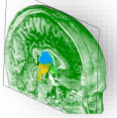


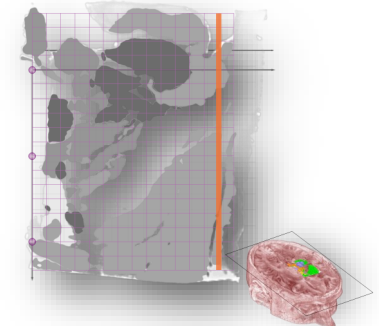
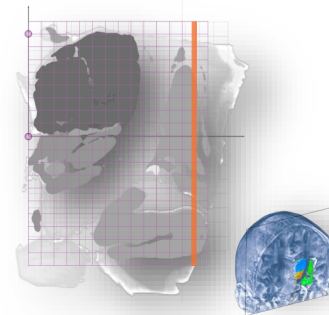
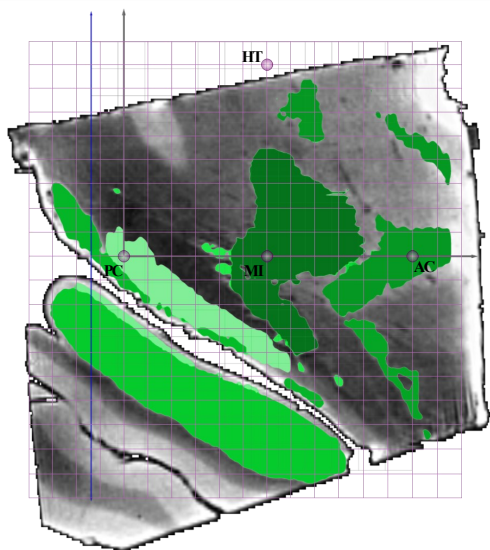
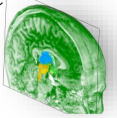

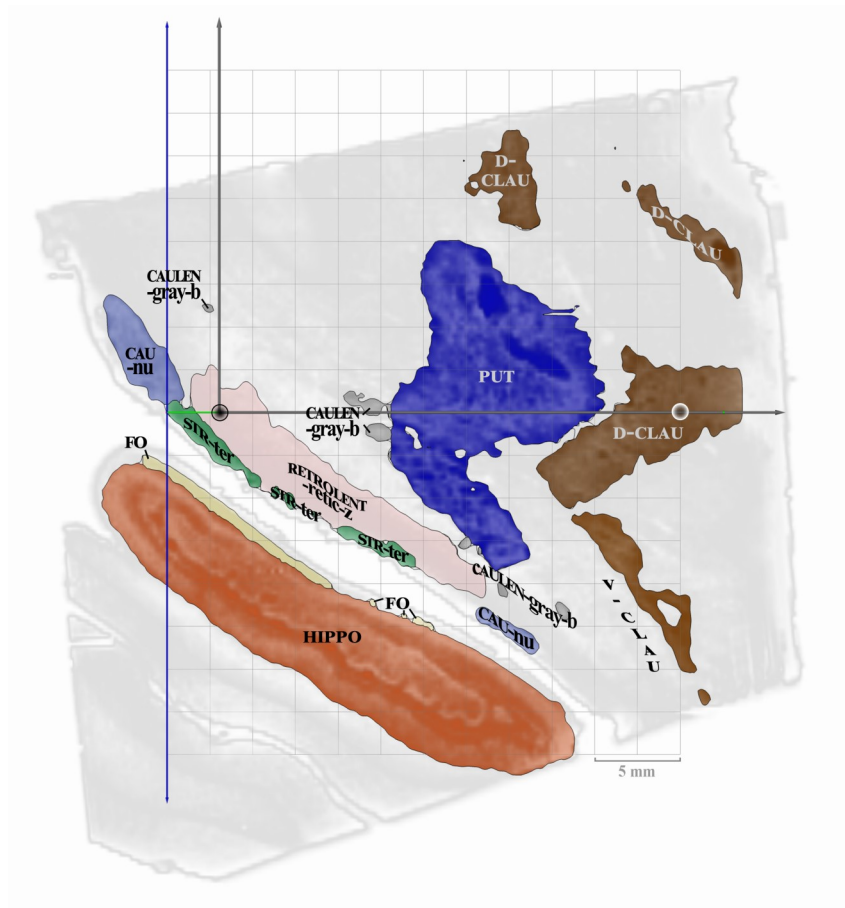


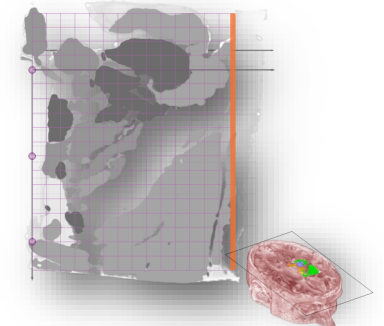
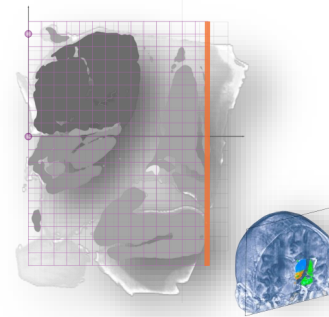
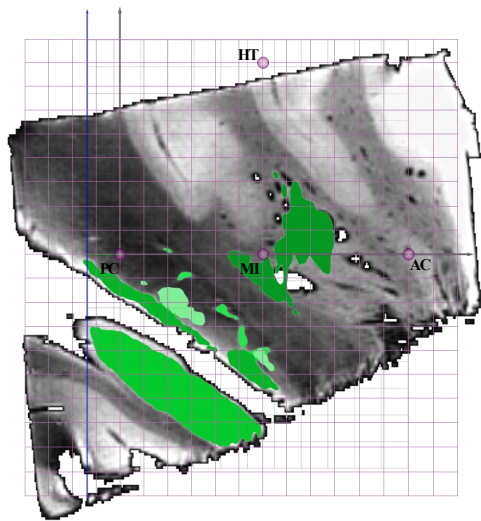
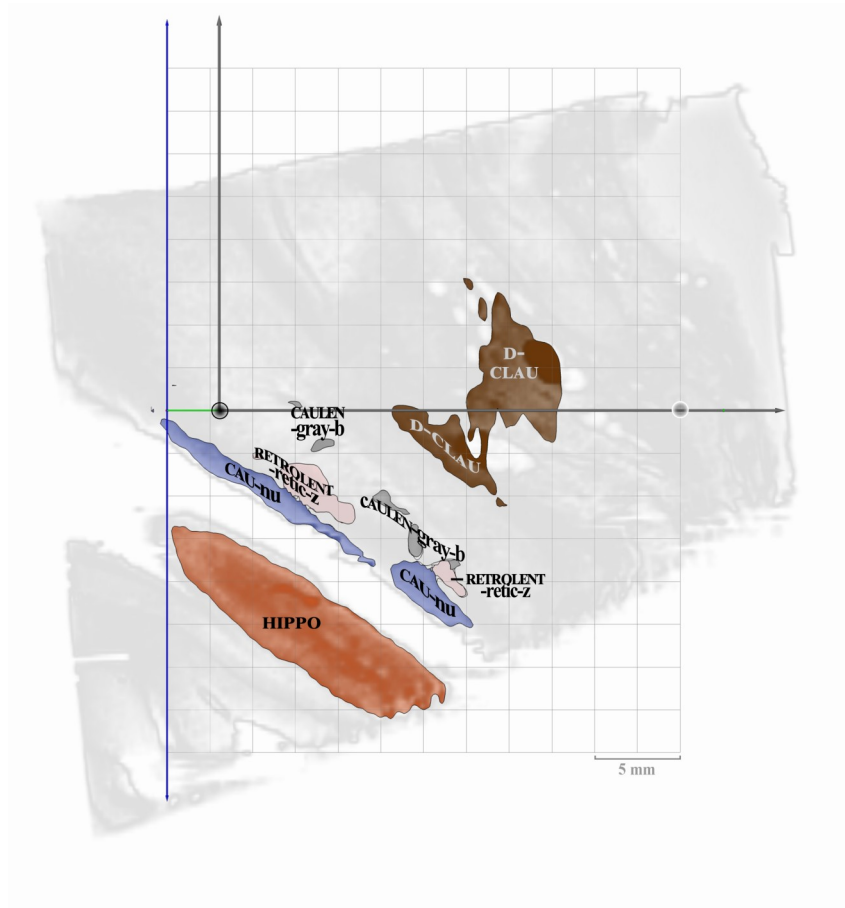
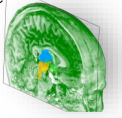










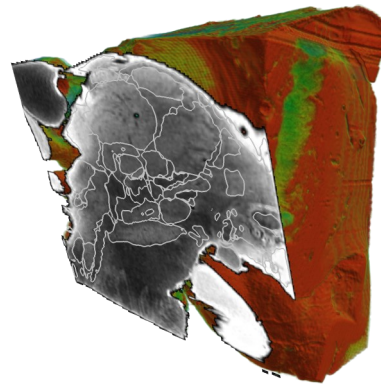


MRI ATLAS OF THE HUMAN DEEP BRAIN

Jean-Jacques Lemaire, MD, PhD, neurosurgeon, University Hospital of Clermont-Ferrand,
Université Clermont Auvergne, CNRS, SIGMA, France



This work is licensed under the Creative Commons Attribution-NonCommercial-NoDerivatives 4.0 International License. To view a copy of this license, visit <http://creativecommons.org/licenses/by-nc-nd/4.0/> or send a letter to Creative Commons, PO Box 1866, Mountain View, CA 94042, USA.



15 SAGITTAL PLATES

February 2019