



# **Somatotomy in the GPi: Analysis of Motor Side Effects during Intraoperative Assessment in a Parkinsonian**

Jerome Coste, Simone Hemm, Miguel Ulla, Philippe Derost, François Caire,  
Franck Durif, Jean-Jacques Lemaire

## **► To cite this version:**

Jerome Coste, Simone Hemm, Miguel Ulla, Philippe Derost, François Caire, et al.. Somatotomy in the GPi: Analysis of Motor Side Effects during Intraoperative Assessment in a Parkinsonian. Journée de la Recherche, Nov 2006, Clermont-Ferrand, France. 2006. hal-02071912

**HAL Id: hal-02071912**

**<https://uca.hal.science/hal-02071912>**

Submitted on 19 Mar 2019

**HAL** is a multi-disciplinary open access archive for the deposit and dissemination of scientific research documents, whether they are published or not. The documents may come from teaching and research institutions in France or abroad, or from public or private research centers.

L'archive ouverte pluridisciplinaire **HAL**, est destinée au dépôt et à la diffusion de documents scientifiques de niveau recherche, publiés ou non, émanant des établissements d'enseignement et de recherche français ou étrangers, des laboratoires publics ou privés.



# Somatotopie observée dans le Gpi: analyse d'effets moteurs indésirables au cours d'une stimulation cérébrale profonde chez un patient parkinsonien

(Somatotopy in the GPi: Analysis of Motor Side Effects during Intraoperative Assessment in a Parkinsonian)

J Coste<sup>(1,2)</sup>; S Hemm<sup>(3)</sup>; M Ulla<sup>(4)</sup>; P Derost<sup>(4)</sup>; F Caire<sup>(3)</sup>; F Durif<sup>(4)</sup>; JJ Lemaire<sup>(1,3)</sup>

(1) Service de Neurochirurgie A, CHU de Clermont Ferrand, Université d'Auvergne, (2) Laboratoire de Neurobiologie de la Douleur Trigéminal (INSERM E216), (3) Equipe de Recherche en Imagerie Médicale (ERIM INSERM-ERI 14), (4) Département de Neurologie, CHU de Clermont Ferrand, Université d'Auvergne.

## INTRODUCTION

A somatotopy inside the human globus pallidus (GP), based on intra operative microelectrode-recordings during passive or active movement and on clinical results of deep brain stimulation (DBS) in movement disorders, has been described in the literature (2,7,9). We aimed at reporting a GP somatotopy, observed in one parkinsonian patient by dystonic motor side effect assessment during acute stimulation, and related to MRI anatomy.

## MATERIAL AND METHODS

### History

A 68-year-old right-handed woman suffered from Parkinson's disease for 16 years, initially affecting the right upper limb with tremor. Before surgery, dyskinesia was encountered for the upper and the lower limbs, for the trunk with alternatively, severe blocking episodes. Moreover, an important bradykinesia was observed with chin and upper limb tremor.

### Surgical technique

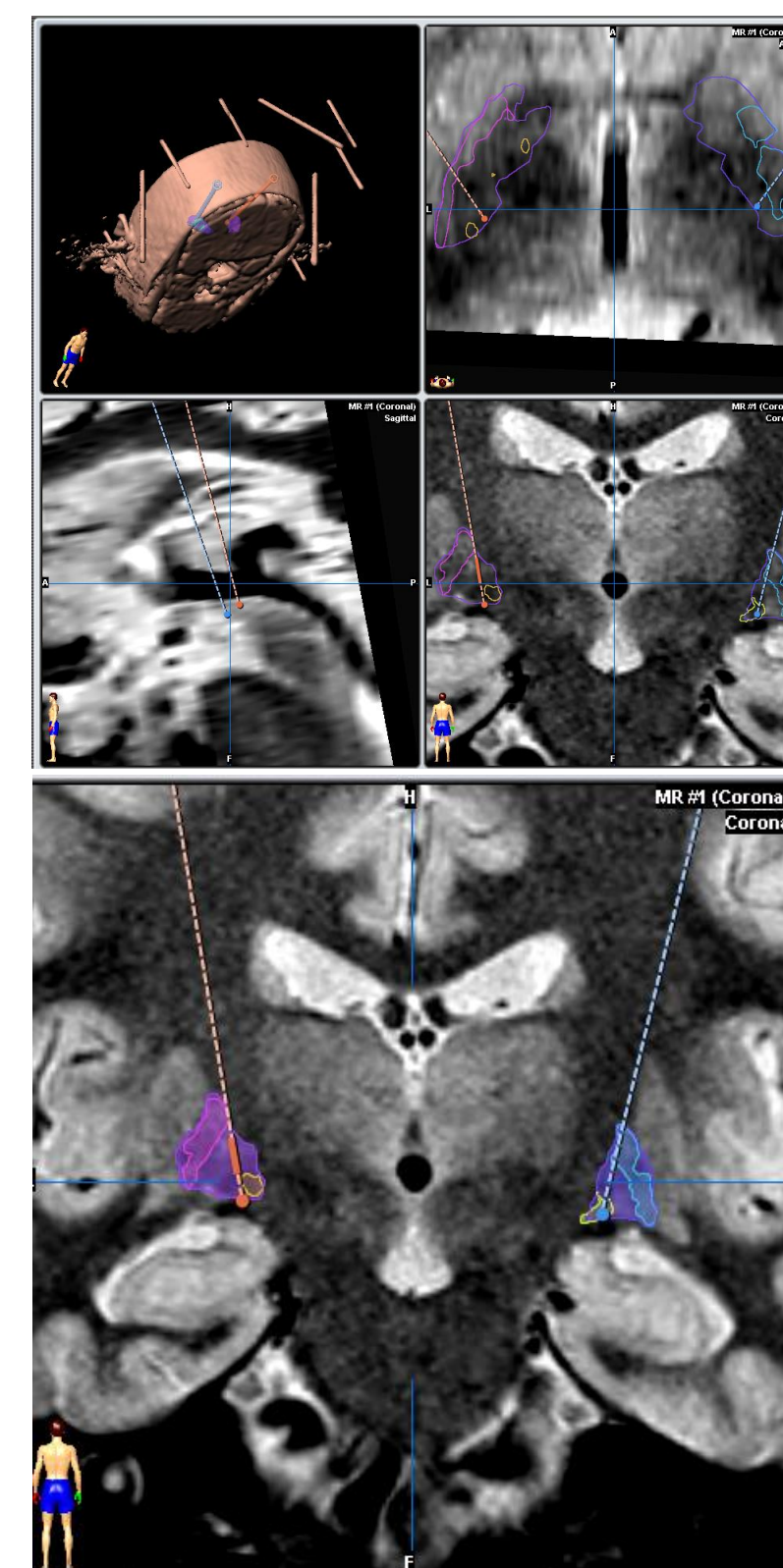
**Stereotactic MRI:** On the first day, the stereotactic Leksell G frame (Elekta, Sweden) was placed with its repositioning kit (Leksell repositioning kit, Elekta, Sweden) under local anesthesia. A stereotactic MRI was performed (Sonata 1.5 Tesla, Siemens, Germany) in three orthogonal planes (axial, coronal and sagittal). The voxel size was  $0.52 \times 0.62 \times 2 \text{ mm}^3$  (field of view = 270 mm; slice thickness = 2 mm). A Turbo Spin Echo (T2-TSE) sequence was used for the axial and the sagittal planes: TR = 8000 msec; TE = 10 msec; 24 images. A White matter Attenuated Inversion Recovery (WAIR) sequence was used for the coronal plane: TR = 4500 msec; TE = 13 msec; TI = 160 msec; 2 x 15 images (two interleaved series). The frame was removed.

**Planning:** Direct targeting of GPi was performed using a stereotactic software (Iplan, BrainLab, Germany). We identified all the segments of the Globus Pallidus (GP). GP is commonly divided in two parts (3,8) the lateral and the medial segments, respectively named external GP (GPe) and internal GP (GPi). An accessory lamina or lamina pallidi incompleta, in a basal and posterior position, partially separates the GPi into a lateral (GPil) and a medial (GPim) subdivisions (4,5,6,8). With the help of probe view reconstructions, we determined a trajectory, with a double obliquity, avoiding the main vessels, going strictly through the parenchyma and with an endpoint located at the lower boundary of the structure: we schematically placed the end point at the junction between the 3<sup>rd</sup> and the 4<sup>th</sup> quarter of GP according to its main antero-posterior axis (1). We planned three parallel tracts, a central one centered on the best anatomical target, a 2mm-lateral one and a 2mm-medial one on the left hemisphere, a central one, a 2mm-anterior one and a 2mm lateral one on the right hemisphere.

**Implantation surgery:** The following day, the stereotactic frame was repositioned. Under local anesthesia, after recording of neuronal activity, an acute stimulation (monophasic, negative current, frequency: 130Hz, pulse width: 0.06msec) was performed using unshielded tungsten microelectrodes (stimulation tip: length 1.2mm, diameter 550µm) with a microguide system (Alpha Omega, Israel). We explored the clinical effects every 1 or 2mm (current up to 5mA) along the distal 10mm on the 3 parallel tracts on each side. Contralateral dystonic movements were noted (mean current =  $0.97 \pm 0.14 \text{ mA}$ ). On the 6 tracts (45 GP checkpoints), the involved body parts (face, upper and lower limbs) were matched with the anatomic structures.

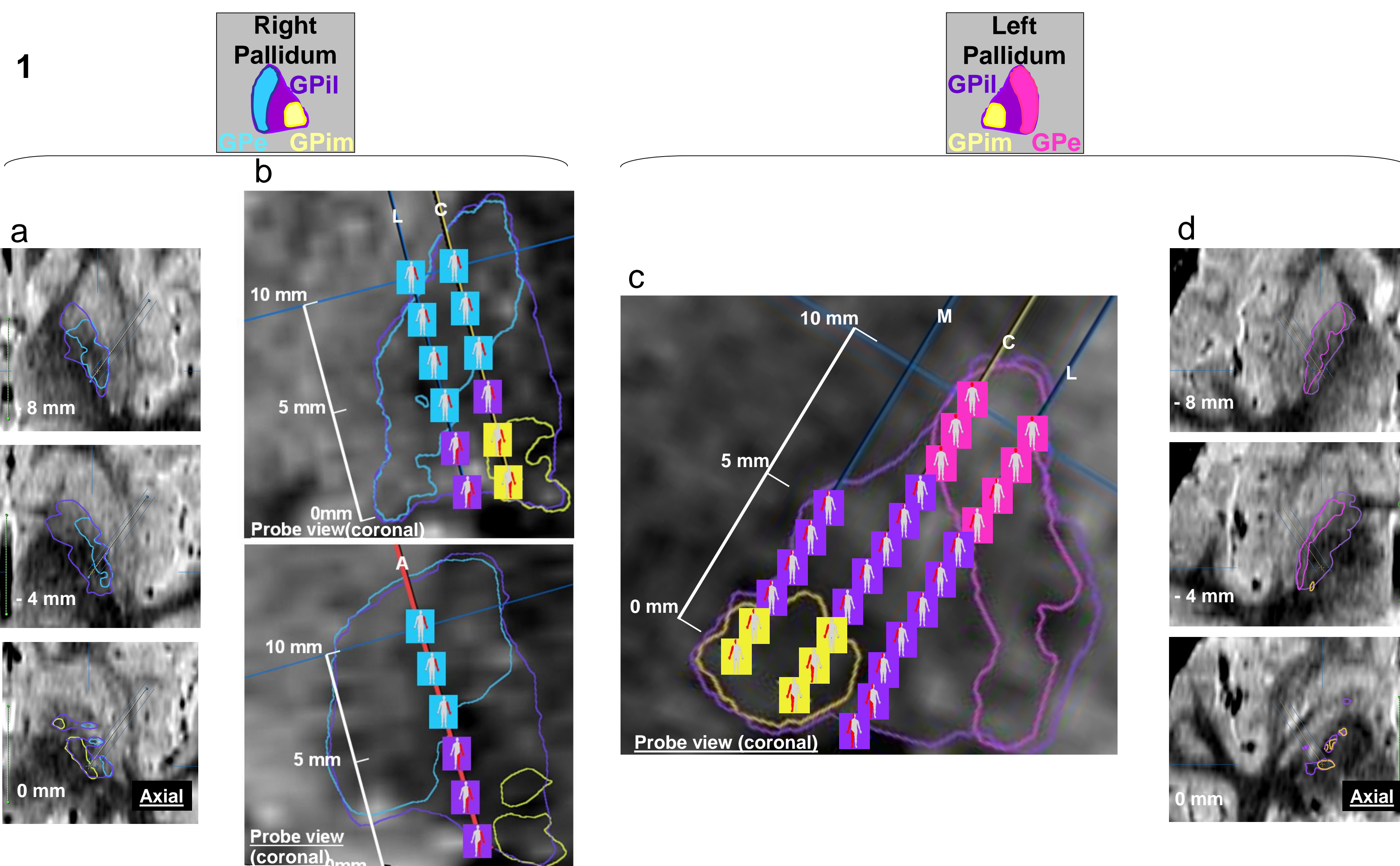
Then a quadripolar electrode (DBS 3387, Medtronic, USA) was placed on the selected tract (the central one for both) with one or two contacts in the clinically most efficient area. Perioperative tele radiographic X-rays controls and postoperative non-stereotactic coronal T2-TSE MRI acquisitions were performed to control the electrode positioning.

Postoperatively, chronic DBS dramatically improved dyskinesia (electrodes implanted on the central tracts).



Surrounding of pallidal subdivisions and trajectory definition.

## A SOMATOTOPY OF DYSTONIC MOTOR SIDE EFFECTS WAS ENCOUNTERED INSIDE EACH PALLIDAL STRUCTURE



GPe, GPi lateral (GPil) and GPi medial (GPim) seemed to be characterized by a segregated body map.

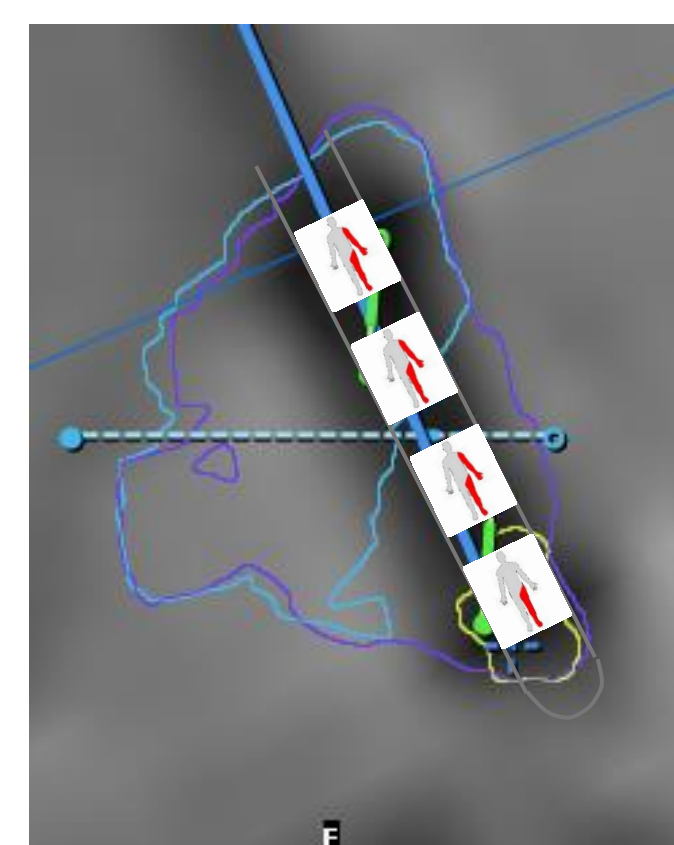
Contralateral dystonic movements were noted during acute intraoperative stimulation and represented as pictograms along the distal 10mm on 3 parallel tracts on each side using probe views. Central (C), anterior (A) and lateral (L) tracts are explored on the Right pallidum and central (C), medial (M) and lateral (L) trajectories on the Left one. A scale represents the 10mm course of the stimulation exploration. (figures 1b and 1c)

Axial slices with surrounded structures are illustrated for the position -8mm, -4mm then 0mm on the central tracts (figures 1a and 1d).

We found inside each structure (GPe, GPil and GPim) a rostro-caudal somatotopic organisation

- face
- upper limb
- lower limb
- superior part
- intermediate part
- inferior part.

2



### Post surgery clinical results.

- Initially, GPi DBS totally abolished dyskinesia.
- 3 months after the surgery
  - adverse effect: dyskinesia improved by voltage.
- 6 months post surgery
  - 80% improvement on dyskinesia (auto evaluation)
  - minor efficiency on other parkinsonian symptoms
  - somatotopy of stimulation induced dystonia found with the Right DBS electrode (figure 2).
  - stimulation parameters: 1.8V, 60µsec and 130Hz

## DISCUSSION

The somatotopic organization analysis is an interesting spin-off of intra operative motor side effect analysis. The GP somatotopy related to these clinical conditions has to be confirmed. Studies have reported a somatotopy of clinical effect [dystonia: (9), dyskinesia (2)] or a spatial organization of kinesthetic cells in Parkinsonian GP (7). Techniques of localization of clinical effects or anatomical structures should influence the results and have to be refined as proposed with our patient based approach.