



**HAL**  
open science

## Analysis of deep brain stimulation electrodes: A semi-automatic approach of contact localization

Sarah Schönfisch, Simone Hemm, Laurent Sarry, Morgane Saingery, Jerome Coste, Jean Gabrillargues, Jean-Jacques Lemaire

### ► To cite this version:

Sarah Schönfisch, Simone Hemm, Laurent Sarry, Morgane Saingery, Jerome Coste, et al.. Analysis of deep brain stimulation electrodes: A semi-automatic approach of contact localization. Kongress der Deutschen Gesellschaft für Biomedizinische Technik im VDE, Sep 2007, Aachen, Germany. 2007. hal-01901586

**HAL Id: hal-01901586**

**<https://uca.hal.science/hal-01901586v1>**

Submitted on 23 Oct 2018

**HAL** is a multi-disciplinary open access archive for the deposit and dissemination of scientific research documents, whether they are published or not. The documents may come from teaching and research institutions in France or abroad, or from public or private research centers.

L'archive ouverte pluridisciplinaire **HAL**, est destinée au dépôt et à la diffusion de documents scientifiques de niveau recherche, publiés ou non, émanant des établissements d'enseignement et de recherche français ou étrangers, des laboratoires publics ou privés.

# Analysis of deep brain stimulation electrodes: A semi-automatic approach of contact localization

S. Schönfisch<sup>1,2</sup>, S. Hemm<sup>2</sup>, L. Sarry<sup>2</sup>, M. Saingery<sup>2</sup>, J. Coste<sup>2,3</sup>, J. Gabrillargues<sup>2,4</sup>, J.J. Lemaire<sup>2,3</sup>

<sup>1</sup>Fachhochschule Oldenburg/Ostfriesland/Wilhelmshaven, Wilhelmshaven, Germany; <sup>2</sup>Inserm, ERI 14, Equipe de Recherche en Imagerie Médicale, Clermont-Ferrand, France; <sup>3</sup>CHU Clermont-Ferrand, Hôpital Gabriel Montpied, Service de Neurochirurgie A, Clermont-Ferrand, France; <sup>4</sup>CHU Clermont-Ferrand, Hôpital Gabriel Montpied, Service de Radiologie A, Clermont-Ferrand, France

## Introduction

Deep brain stimulation (DBS) has proven to be a highly efficient treatment for Parkinson's disease (PD). By stereotactic surgery, 4-contact electrodes (Activa 3389, Medtronic, Minneapolis, USA) can be placed very precisely in the brain. To improve the understanding of the mechanism of action of DBS it is necessary to analyze precisely the anatomical position of each electrode contact and to compare it to the corresponding clinical outcome. Such an analysis necessitates preoperative anatomic images, a postoperative anatomic image series (electrode artifact) and the correspondence between both image series (transformation parameters). We propose in this study a tool able to **semi-automatically identify contact positions on preoperative CT or MR images and their projection on the preoperative image** for detailed anatomic analysis. The results obtained with this method were compared to those obtained by manual identification for eight patients.

## Materials and Methods

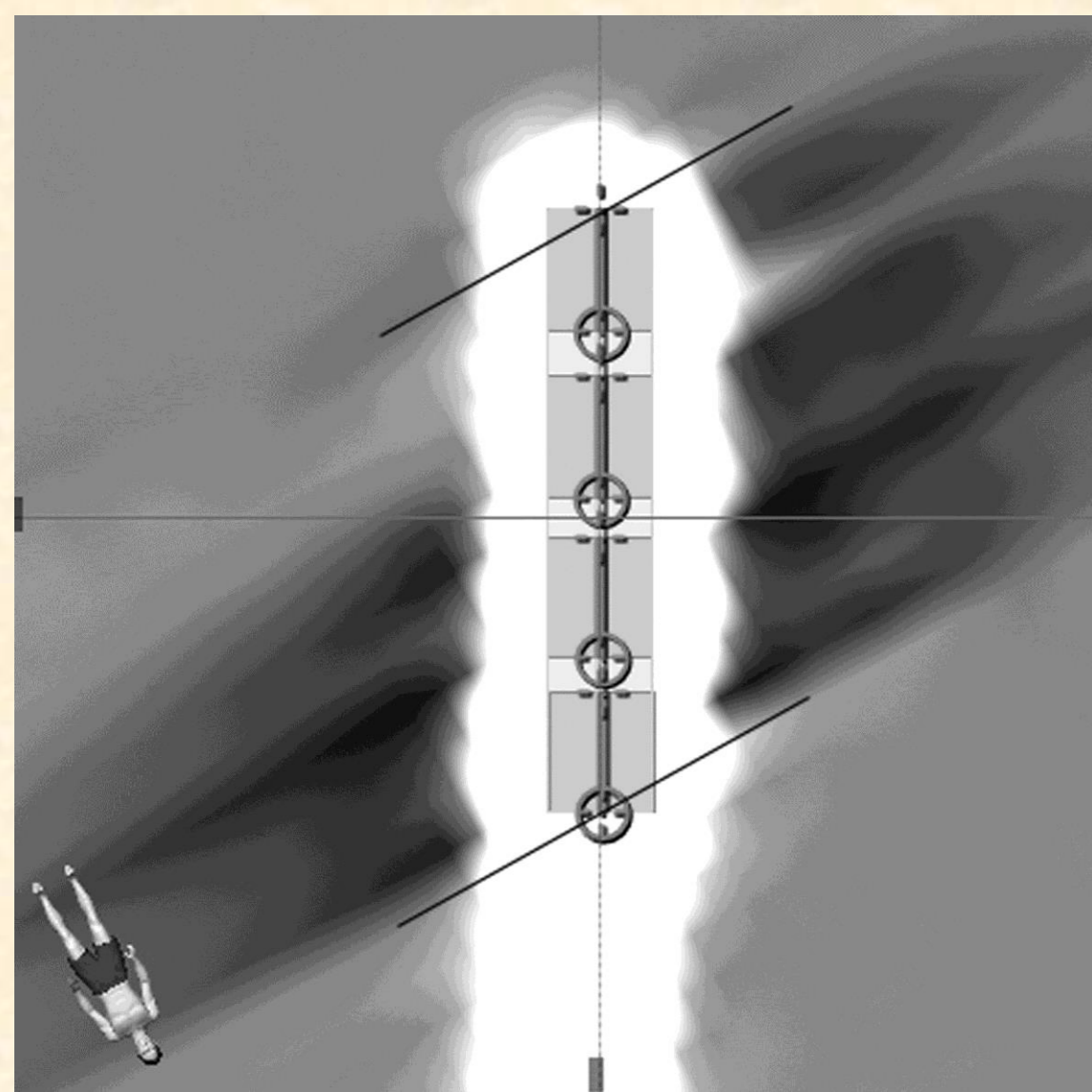
### Image data

#### •Preoperative stereotactic MRI (Siemens)

- White Matter Attenuated Inversion Recovery (WAIR) T2-weighted sequence
- TR: 4500 msec; TE: 13 msec; Voxel size: **0.52x0.52x2.00 mm<sup>3</sup>**

#### •Postoperative CT (GE)

- rotation time of 1s, tube voltage 140 kV, effective mAs of 280
- isotropic voxel size after axial reconstruction of **0.43x0.43x0.43 mm<sup>3</sup>**



#### a) Manual electrode identification

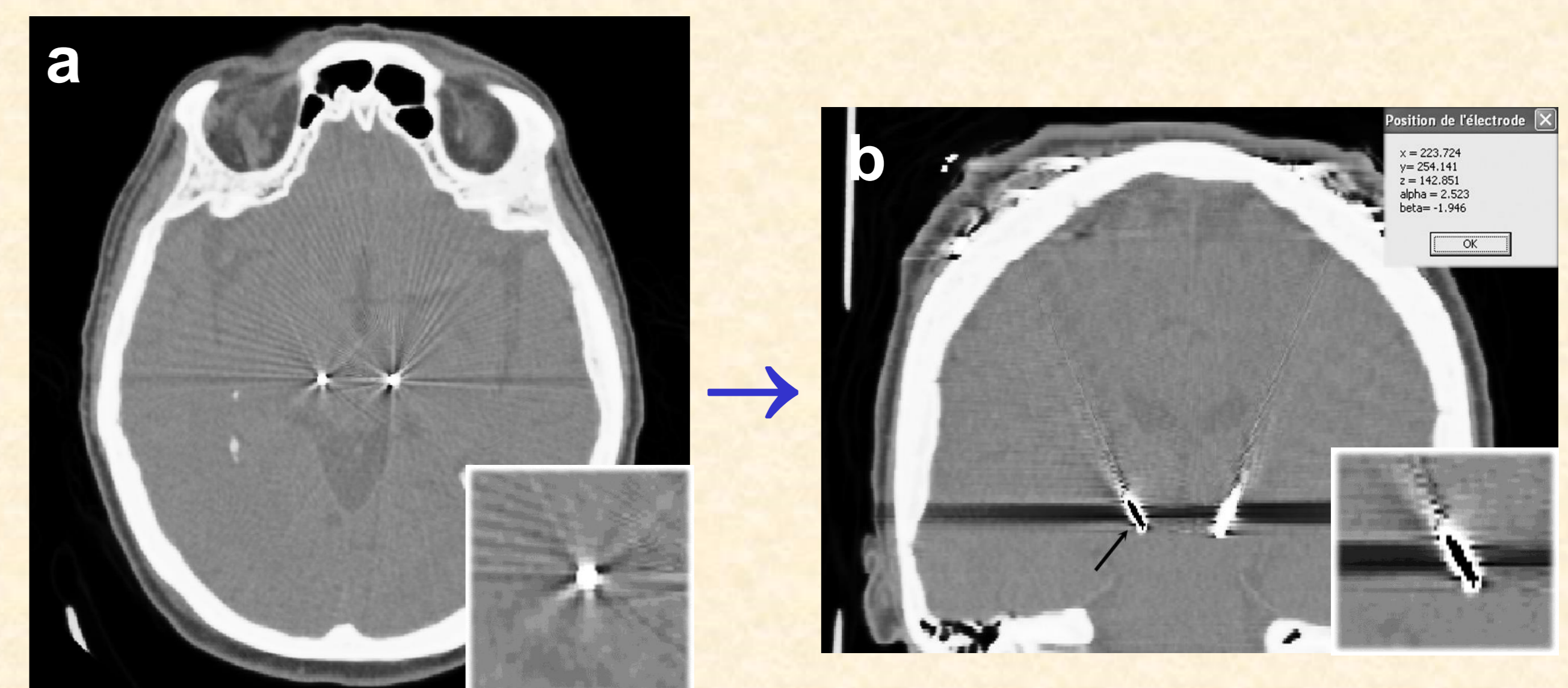
- Merging of preoperative MR images and postoperative CT scan (iPlan, Brainlab, Munich) – mutual information algorithm
- Artifact analysis on the CT scan using the stereotactic planning software (iPlan, Brainlab, Munich) (**Figure 1**)
  - Middle of artifact in axial direction = electrode
  - Lateral black artifacts = beginning and end of the electrode
  - Deduction of the four electrode contacts and their centers on the CT image
- Extraction of the MR image coordinates (possible due to image fusion) of the contact centers via a neuronavigational software (VVLink, Brainlab, Munich)

**Figure 1:** Identification of the final electrode contact positions via the CT artefact

#### b) Semi-automatic electrode identification

Two routines were developed (Borland C++ Builder) to semi-automatically identify the electrode contacts based on the homemade software ImageLib:

- 1) - indication of the tip and the direction of the electrode in the postoperative image (**Figure 2a**) by the user
  - calculation of the contact position in image coordinates by the software (**Figure 2b,c**)
    - minimization of the squared difference between the expected intensity in artifact center and the voxel intensities
    - electrode contacts sampled in radial way (tricubic interpolation to obtain sub-voxel accuracy)
- 2) - extraction of the transformation parameters between both image series given by the iPlan software
  - calculation of the corresponding MR image coordinates and visualization of the determined contacts (center) on the preoperative image (**Figure 2d**)



**Figure 2:** Semi-automatic electrode contact identification and visualisation on preoperative images

$$\bar{p}' = R\bar{p} + t$$

- R = Rotation
- T = Translation
- p = electrode contact coordinates

Position des centres			
Premier contact :	x =	219.235	
	y =	250.700	
	z =	144.216	
Second contact :	x =	221.933	
	y =	252.356	
	z =	143.948	
Troisième contact :	x =	224.631	
	y =	254.012	
	z =	143.679	
Quatrième contact :	x =	227.328	
	y =	255.668	
	z =	143.411	

#### c) Comparison of results obtained with both methods for eight Parkinson patients treated by DBS

## Results

- Feasibility for all eight patients
- Difference between results obtained with both methods are low
- Mean values < pixel size/ slice thickness (**Table 1**)
- Semi-automatic detection = simple to apply;
- Manual detection = specialist necessary

mm	$\Delta x$	$\Delta y$	$\Delta z$
<b>Mean <math>\pm</math> SD</b>	0.31 $\pm$ 0.19	0.14 $\pm$ 0.13	0.44 $\pm$ 0.36
<b>Min/ Max</b>	0.01/ 0.69	0.01/ 0.50	0.01/ 1.23

**Table 1:** Differences between manually and semi-automatically identified contact coordinates in x, y and z-direction

## Discussion

Results show a low mean error compared to slice thickness and pixel size of MR and CT images. The maximal error in the z-direction of 1.23 mm could be due to uncertainties at several levels. In conclusion, we can say that our automatic tool makes the contact localization more objective. Its application can be enlarged to postoperative MR images and to other diseases treated by electrical stimulation. In the future, it should be envisaged to visualize the contact in its dimension on the preoperative MR images (1.5mm height, 1.3mm diameter) in order to further increase the precision of the anatomic position analysis.