



HAL
open science

Selective cerebral response to autobiographical memory in the persistent vegetative state: a fMRI case study

Anna Sontheimer, Bénédicte Pontier, Jerome Coste, Basile Roche, Thierry
Gillart, Jean Gabrillargues, Jean-Jacques J Lemaire

► To cite this version:

Anna Sontheimer, Bénédicte Pontier, Jerome Coste, Basile Roche, Thierry Gillart, et al.. Selective cerebral response to autobiographical memory in the persistent vegetative state: a fMRI case study. 1st International Symposium on Deep Brain Connectomics, Sep 2012, Clermont-Ferrand, France. hal-01871536

HAL Id: hal-01871536

<https://uca.hal.science/hal-01871536>

Submitted on 19 Sep 2018

HAL is a multi-disciplinary open access archive for the deposit and dissemination of scientific research documents, whether they are published or not. The documents may come from teaching and research institutions in France or abroad, or from public or private research centers.

L'archive ouverte pluridisciplinaire **HAL**, est destinée au dépôt et à la diffusion de documents scientifiques de niveau recherche, publiés ou non, émanant des établissements d'enseignement et de recherche français ou étrangers, des laboratoires publics ou privés.

Selective cerebral response to autobiographical memory in the persistent vegetative state : a fMRI case study

A Sontheimer^(1,2), B Pontier^(1,3), J Coste^(1,2), B Roche⁽¹⁾, T Gillart^(1,4), J Gabrillargues^(1,5), JJ Lemaire^(1,2)

(1) Image-Guided Clinical Neurosciences and Connectomics, IGCNC, EA 7282, Université d'Auvergne, Clermont-Ferrand, France

(2) Service de Neurochirurgie A, CHU de Clermont-Ferrand, France

(3) Service de Médecine Physique et Réadaptation, CHU de Clermont-Ferrand, France

(4) Département d'Anesthésie-Réanimation, CHU de Clermont-Ferrand, France

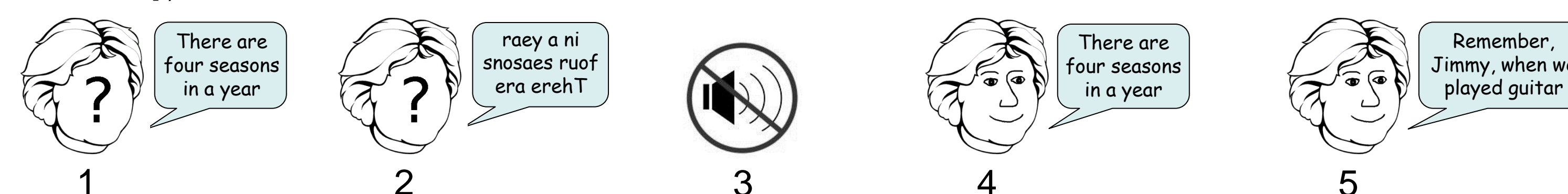(5) Service de Radiologie A, Unité de Neuroradiologie, CHU de Clermont-Ferrand, France

INTRODUCTION

- The vegetative state is characterized by the absence of awareness of self or the environment and preserved autonomic functions¹. Clinical assessment of awareness is based on the observation of voluntary behavioural responses to visual, auditory, tactile or noxious stimuli². Thus, in patients with voluntary motor function impairment, standard clinical approach can lead to misdiagnosis concerning their level of consciousness.
- Functional neuroimaging may be useful in the identification of residual cognitive function in such patients³, in particular to detect speech perception⁴ and comprehension^{5,6,7}.
- We designed a fMRI experiment in order to determine the influence of the emotional charge of speech on its processing, in patients with disorders of consciousness.

SUBJECTS, MATERIAL AND METHODS

- We investigated the case of a 32-year-old, right-handed man, who has sustained severe traumatic brain injury 12 years before. According to clinical testing, the patient was considered to be in persistent vegetative state (CRS-R score = 6.4 ± 1.1 , based on 15 observations during the last 2 months)⁸.
- fMRI scanning was performed during passive language auditory processing tasks, using a block design with five conditions: 1/Narratives with neutral content spoken by an unfamiliar voice, played forward. 2/Narratives with neutral content spoken by an unfamiliar voice, played backward. 3/Silence. 4/Narratives with neutral content spoken by a familiar voice, played forward. 5/Narratives with autobiographical content spoken by a familiar voice, played forward. (Images were acquired on a 3T GE Discovery MR750. fMRI was performed using a whole brain gradient-echo EPI sequence [TR = 3000 ms, TE = 30 ms, resolution = $3.75 \times 3.75 \times 4 \text{ mm}^3$]).



- Several contrasts were analyzed⁹, and compared to three healthy voluntary subjects (all right-handed, mean age of 23.7 ± 0.9 years), in order to isolate the following components: 1,4 and 5 versus 3: Speech auditory processing 1 versus 2: Speech linguistic processing 4 versus 1: Effect of voice familiarity 5 versus 4: Effect of emotional charge of speech

RESULTS

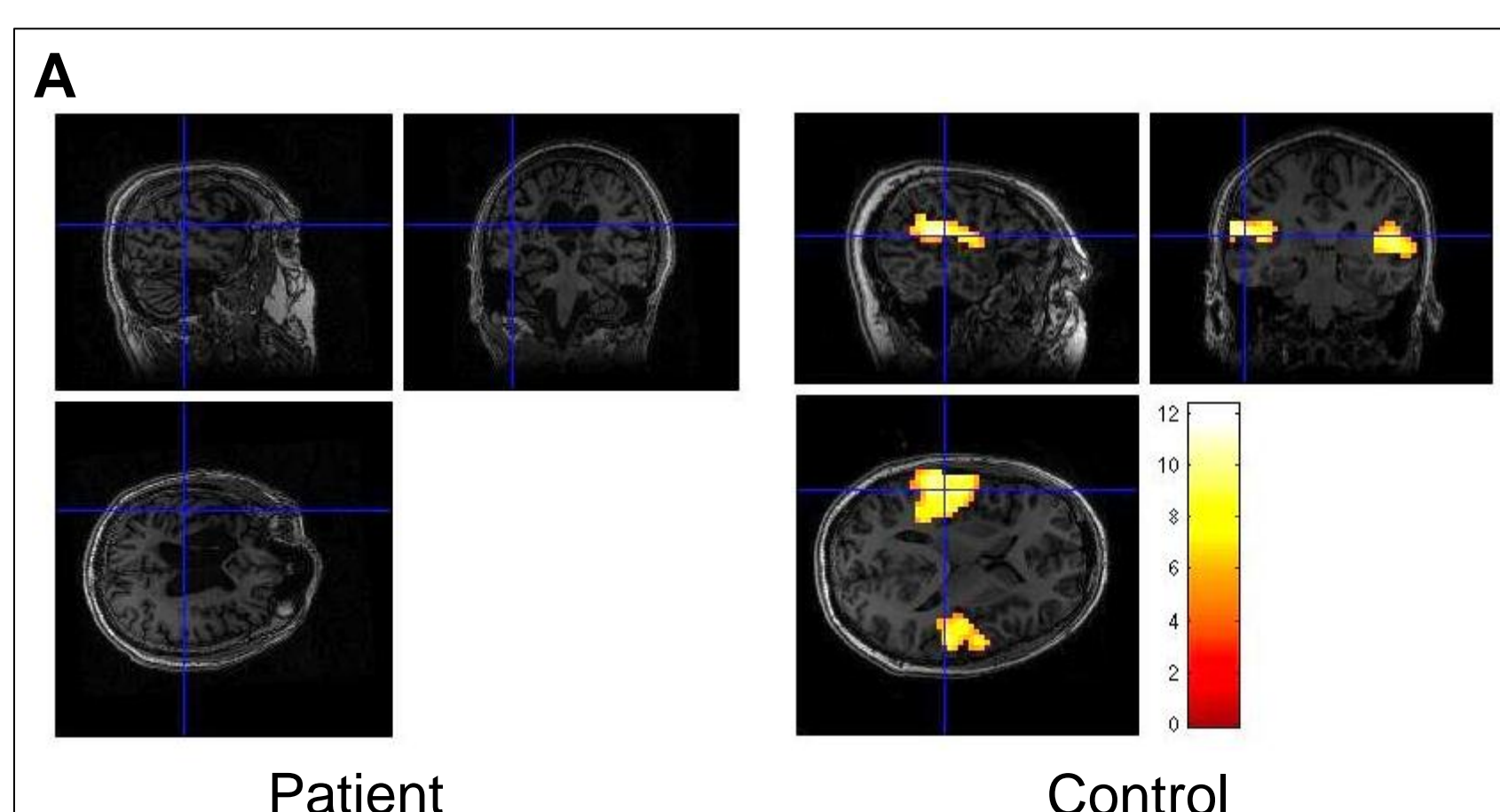


Figure A: Speech auditory processing (Neutral content / Unfamiliar voice) in patient and control (*t*-test; $p < 0.05$ FWE-corrected). The control subjects showed significantly greater activation in bilateral primary (BA 41,42) and associative (BA 22) auditory cortices. The patient failed to show significant activation.

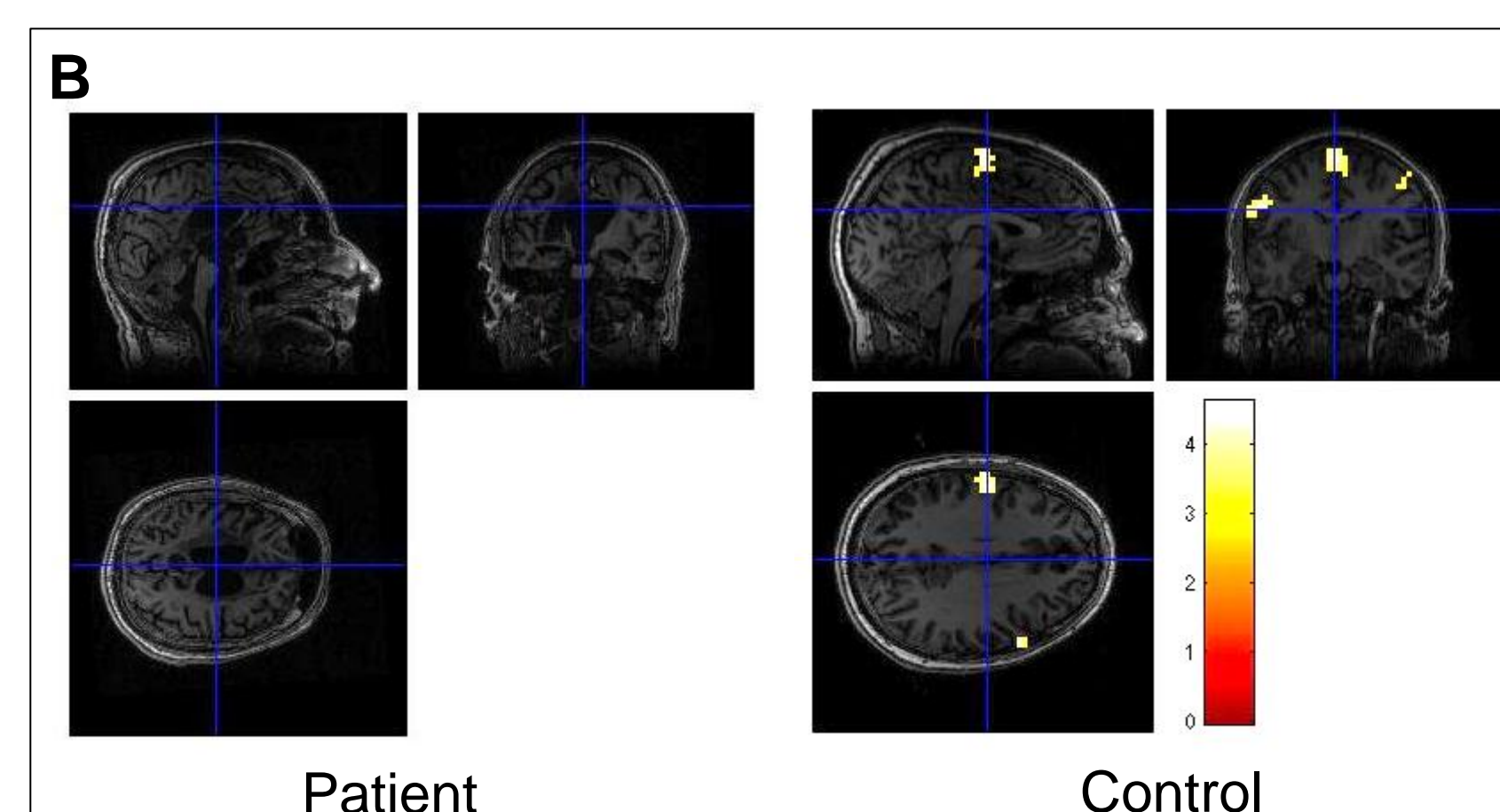


Figure B: Speech linguistic processing (*t*-test; $p < 0.001$ uncorrected). The control subjects showed significantly greater activation in bilateral secondary motor cortices (SMA, PMA) and left temporal pole (not shown). The patient failed to show significant activation.

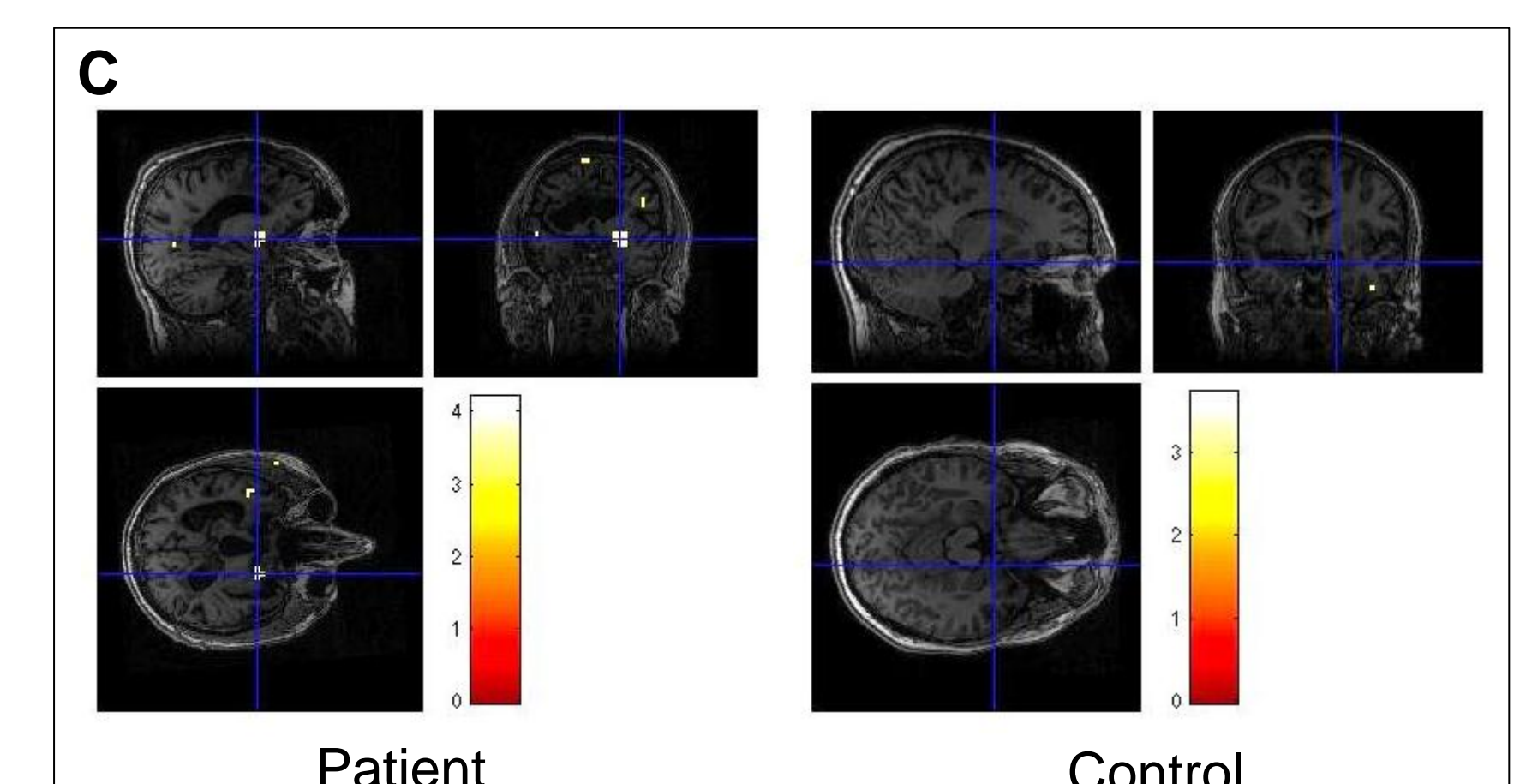


Figure C: Effect of voice familiarity (*t*-test; $p < 0.001$ uncorrected). The patient was more sensitive than the control subjects to voice familiarity, with significantly greater activation in particular in right amygdala and basal ganglia.

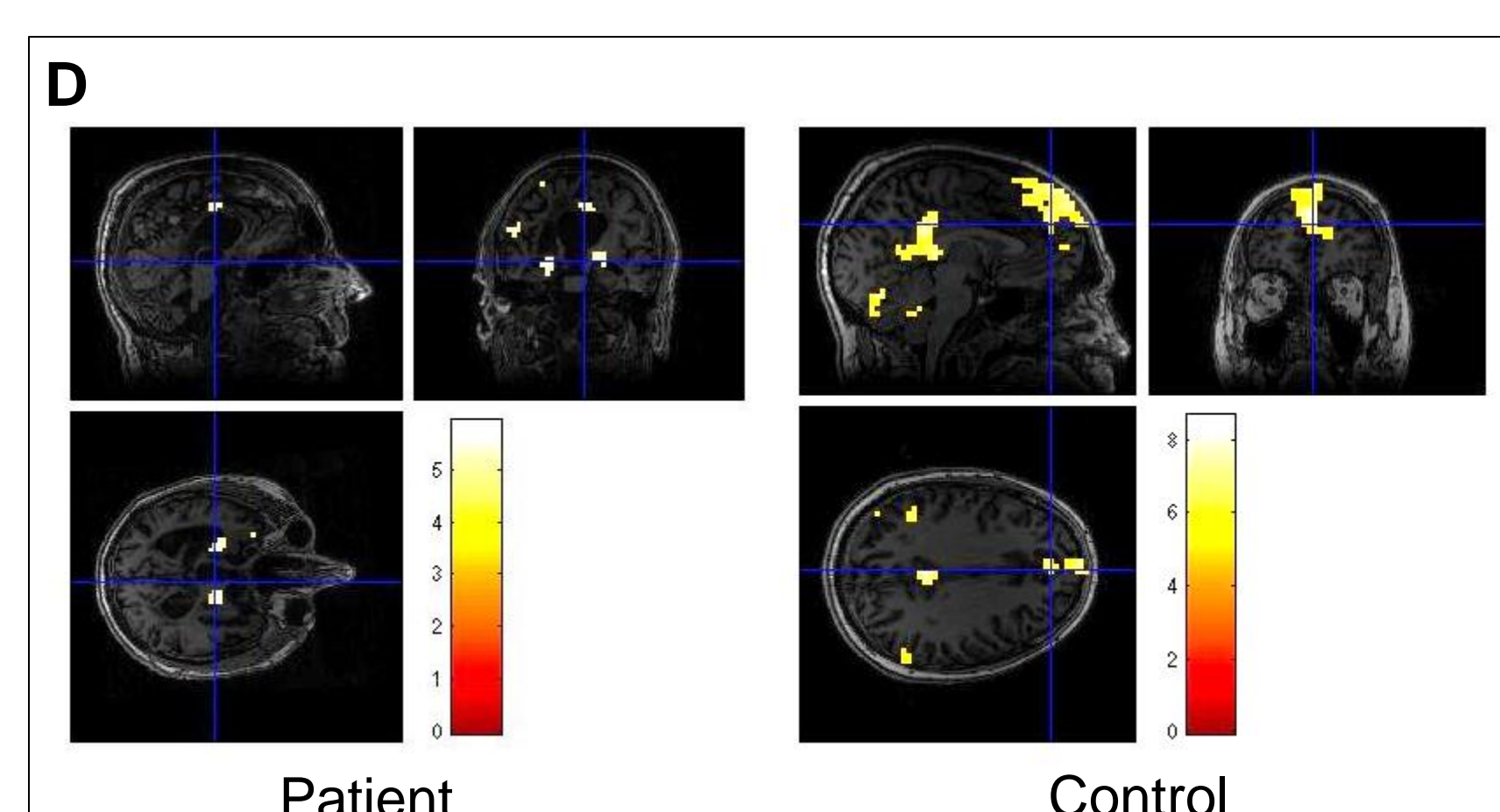


Figure D: Effect of emotional charge of speech (*t*-test; $p < 0.05$ FWE-corrected). In control subjects, listening to autobiographical memories in contrast to neutral narratives leads to significantly greater activity in medial prefrontal cortex, posterior and retrosplenial cingulate cortex, bilateral supramarginal gyri and cerebellum. The patient showed significantly greater activity in cingulate cortex, hippocampi, right basal ganglia and left supramarginal gyrus.

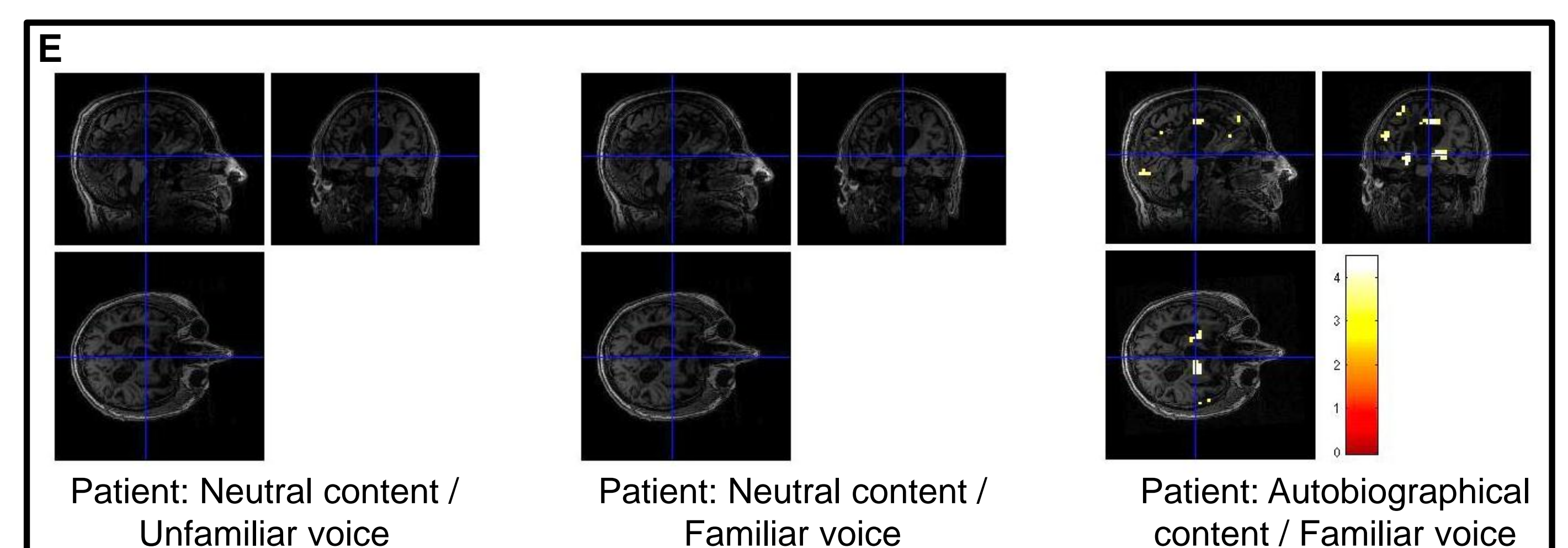


Figure E: Speech auditory processing in patient (*t*-test; $p < 0.001$ uncorrected). No activation was provided in the patient's brain by listening to neutral narratives, whether the voice was familiar or not. On the contrary, a familiar voice telling autobiographical memories brought about a significantly greater activation in medial prefrontal cortex, cingulate cortex, primary visual cortex (BA 17), hippocampi, right basal ganglia and left supramarginal gyrus.

CONCLUSION

- In summary, contrary to the diagnostic criteria defining the vegetative state, the patient showed a cerebral activity in response to autobiographical narratives. Furthermore the observed activation pattern, widely distributed in regions known to be involved in memory retrieval, is coherent with the nature of speech content.
- The present study provides further evidence of possible residual cognitive functions in the vegetative state, and highlights the importance of emotional charge of speech to pass through an attentional filter, of which selectivity might be altered by cerebral lesions. These findings may have implications in neurorehabilitation programs.

REFERENCES

- Jennett B, Plum F. 1972. *Lancet*.
- Kalmar K, Giacino JT. 2005. *Neuropsychological Rehabilitation*.
- Owen AM, Coleman MR. 2008. *Ann. N.Y. Acad. Sci.*
- Coleman MR et al. 2007. *Brain*.
- Fernandez-Espejo D et al. 2008. *Brain Injury*.
- Di HB et al. 2007. *Neurology*.
- Schiff ND et al. 2005. *Neurology*.
- Schnakers et al. 2008. *Brain Injury*.
- <http://www.fil.ion.ucl.ac.uk/spm/software/spm8/>